

9

Urinary tract and perineum

Key Points



9.1 THE URINARY BLADDER

URINARY RETENTION

- Acute retention of urine is an indication for emergency drainage of the bladder
- The common causes of acute retention in the male are urethral stricture and benign prostatic hypertrophy
- Other causes of acute retention are urethral trauma and prostatic cancer
- If the bladder cannot be drained through the urethra, it requires supra-pubic drainage.



9.1 THE URINARY BLADDER

URINARY RETENTION

- In chronic retention of urine, because the obstruction develops slowly, the bladder is distended (stretched) very gradually over weeks, so pain is not a feature .
- The bladder often overfills and the patient with chronic retention presents with dribbling of urine, referred to as “retention with overflow”.



9.1 THE URINARY BLADDER

URINARY RETENTION

- Urethral catheterization or bladder puncture is usually adequate, but cystostomy may become necessary for
 - the removal of a bladder stone or foreign body, or
 - more prolonged drainage, for example after rupture of the posterior urethra or
 - if there is a urethral stricture with complications.
- If a catheter's balloon fails to deflate, inject 3 ml of ether into the tube leading to the balloon. This will rupture the balloon. Cut it off and remove it.
- Prior to removing the catheter, irrigate the bladder with 30 ml of saline.



9.1 THE URINARY BLADDER

URINARY RETENTION

- **Emergency drainage of the bladder in acute retention may be undertaken by:**
 - **Urethral catheterization**
 - **Suprapubic puncture**
 - **Suprapubic cystostomy.**



9.1 THE URINARY BLADDER

URINARY RETENTION

- Treatment of chronic retention is not urgent, but drainage of the bladder will help you to determine the volume of residual urine and prevent renal failure, which is associated with retention.
- Arrange to refer patients with chronic urinary retention for definitive management.



9.1 THE URINARY BLADDER

Urethral Catheterization in the male patient

Technique

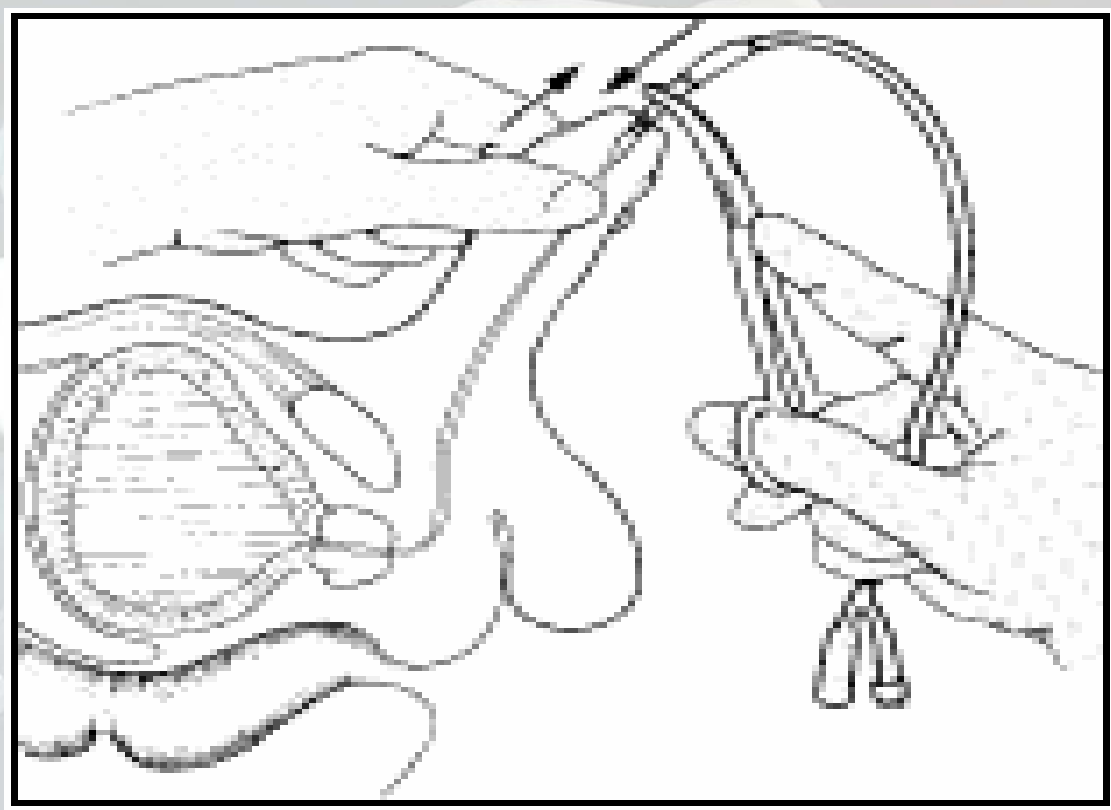


Figure 9.1

9.1

THE URINARY BLADDER Fixation of the Catheter

- If you fail to pass a catheter, proceed to filiforms and followers (Figure 9.2) or use a Foley catheter with a guide.
- If these procedures are unsuccessful, abandon them in favour of suprapubic puncture.
- Forcing the catheter or a metal bougie can create a false passage, causing urethral bleeding and intolerable pain, and increasing the risk of infection.




Figure 9.2

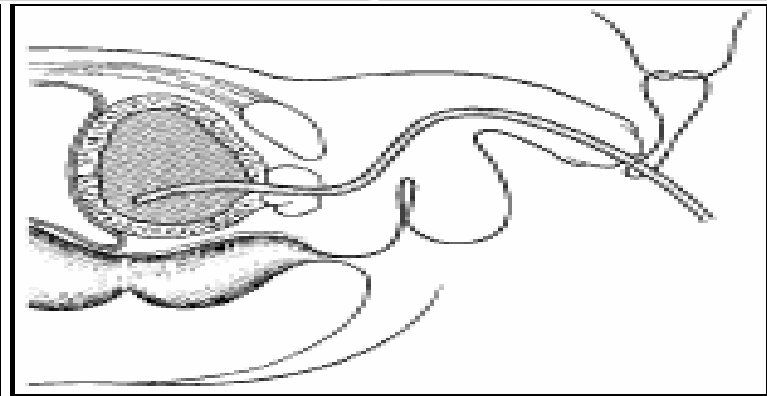


Figure 9.3

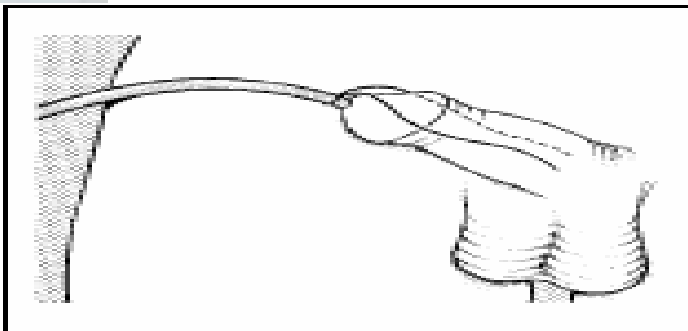


Figure 9.4

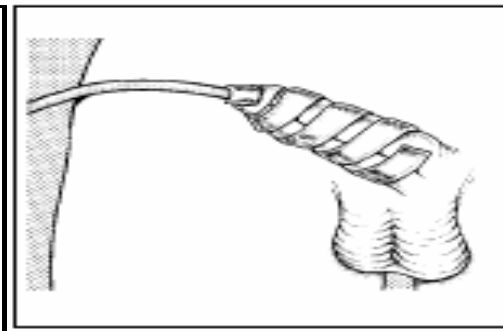


Figure 9.5

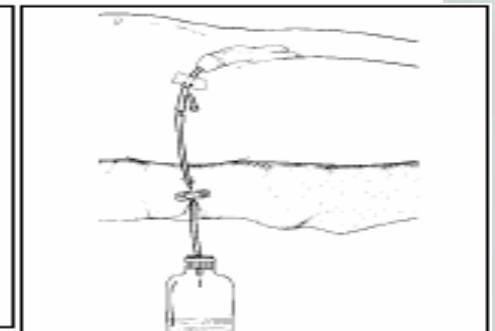


Figure 9.6



9.1

THE URINARY BLADDER

Suprapubic Puncture

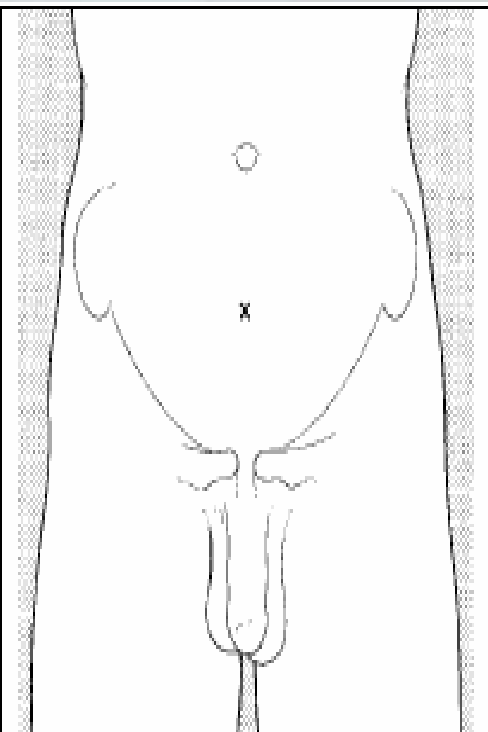


Figure 9.7

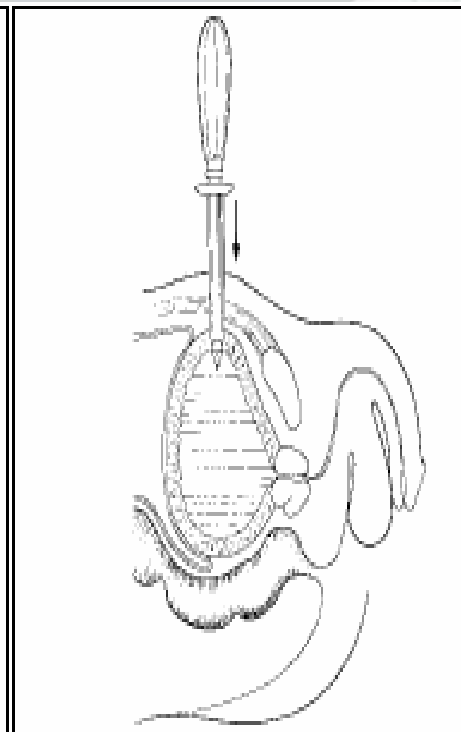


Figure 9.8

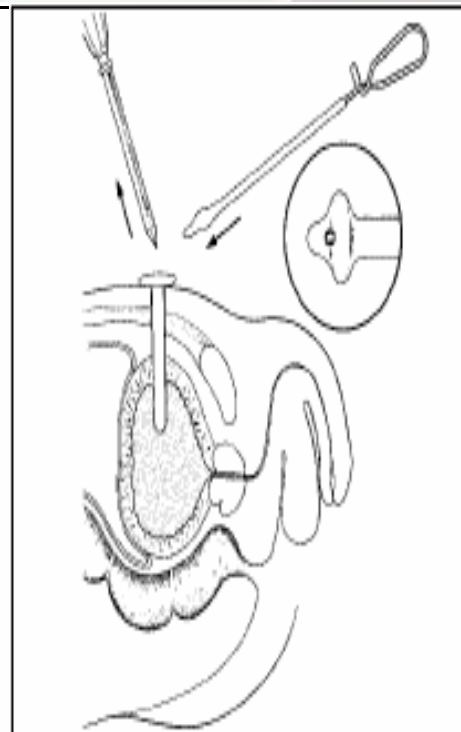


Figure 9.9

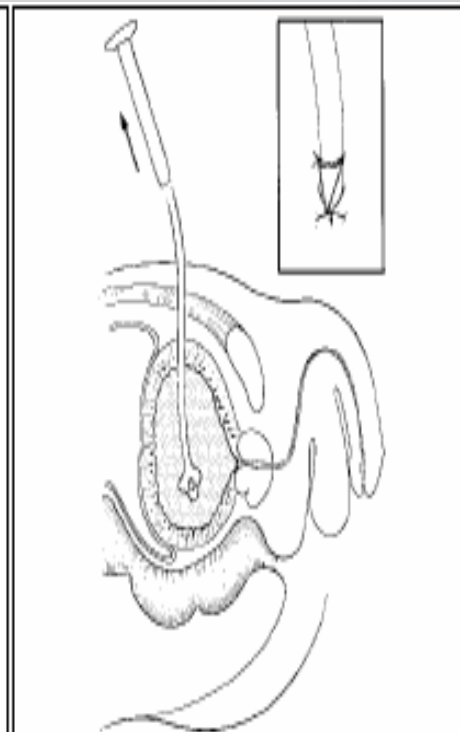


Figure 9.10

9.1

THE URINARY BLADDER Suprapubic Cystostomy

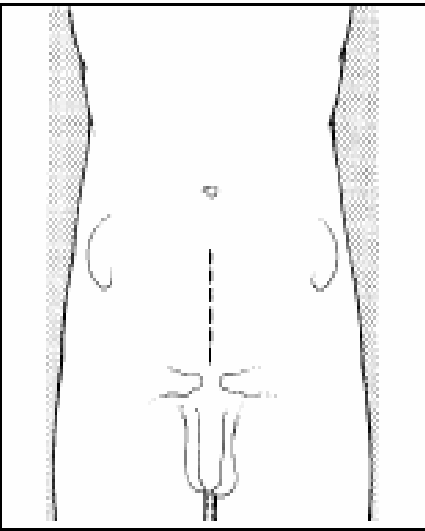


Figure 9.11

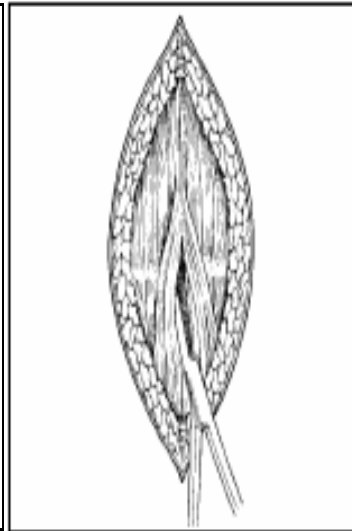


Figure 9.12

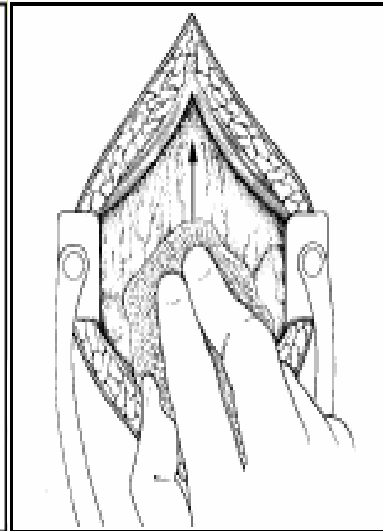


Figure 9.13

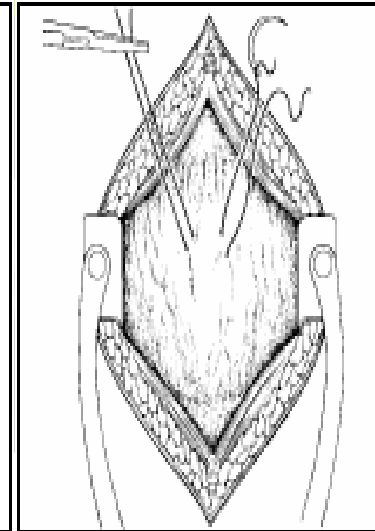


Figure 9.14

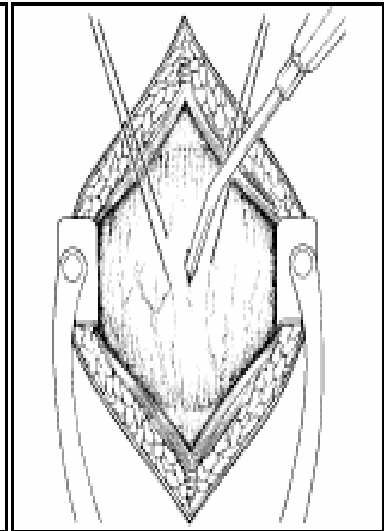


Figure 9.15

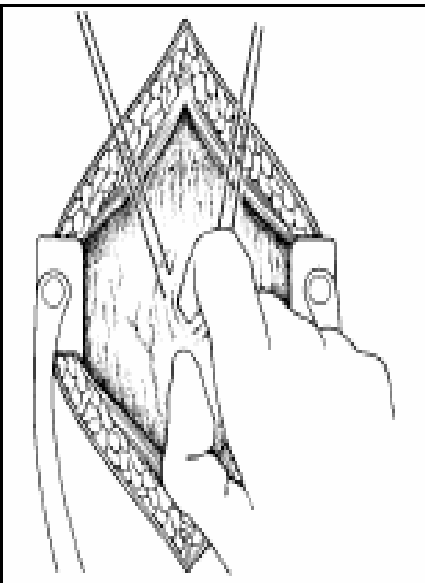


Figure 9.16

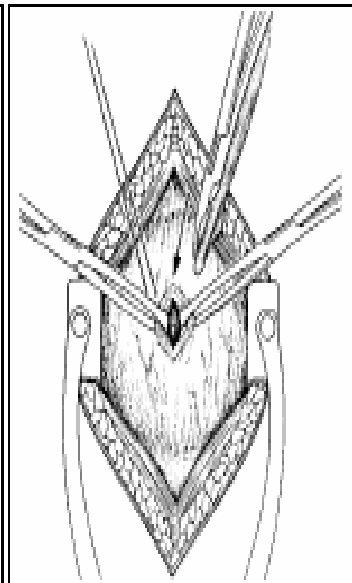


Figure 9.17

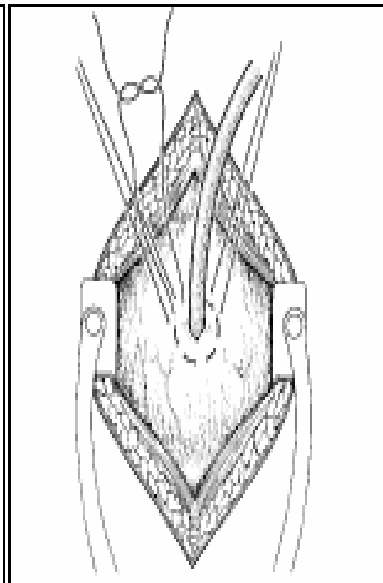


Figure 9.18

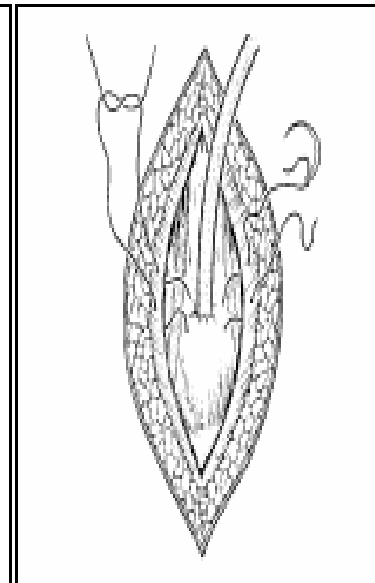


Figure 9.19

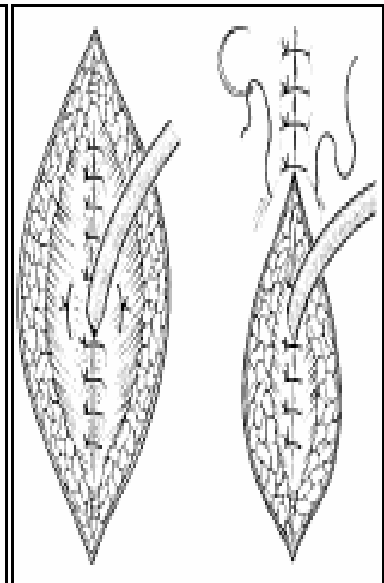


Figure 9.20

9.2 THE MALE URETHRA

Urethral Stricture

- **Filiforms and followers are the safest means of dilating acute strictures**
- **Chronic strictures** can be managed safely with repeat dilations using metal bougies
- **Suprapubic puncture or cystostomy should not be thought of as the last resort and are much preferable to continued instrumentation, which can lead to urethral traumatization.**



9.2 THE MALE URETHRA

Urethral Stricture

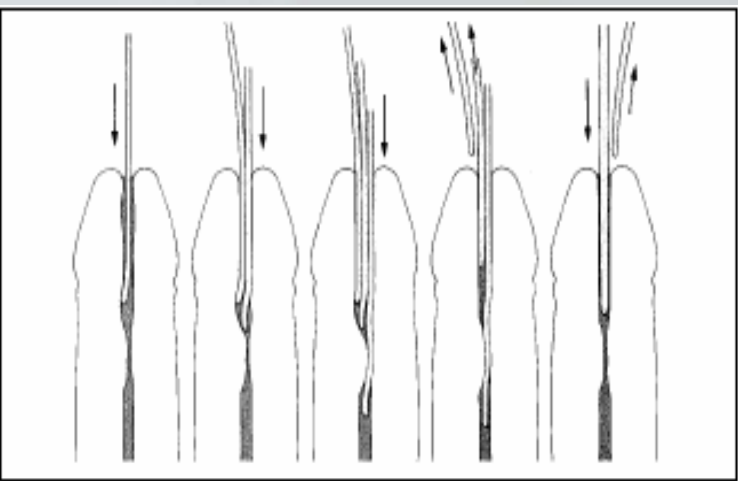


Figure 9.21

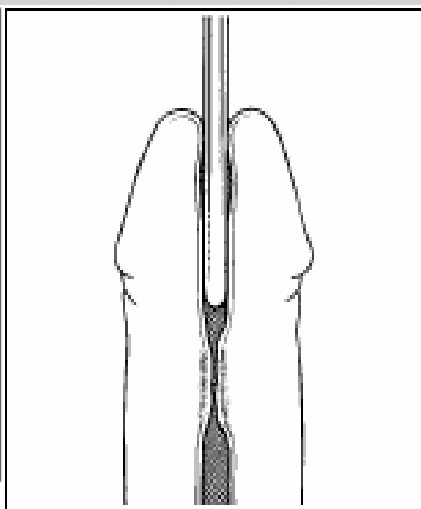


Figure 9.22

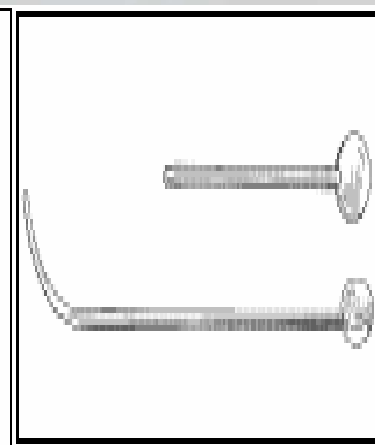


Figure 9.23

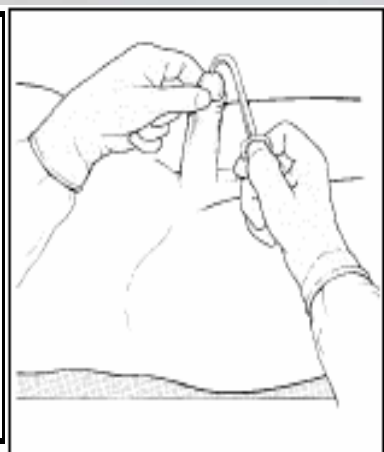


Figure 9.24

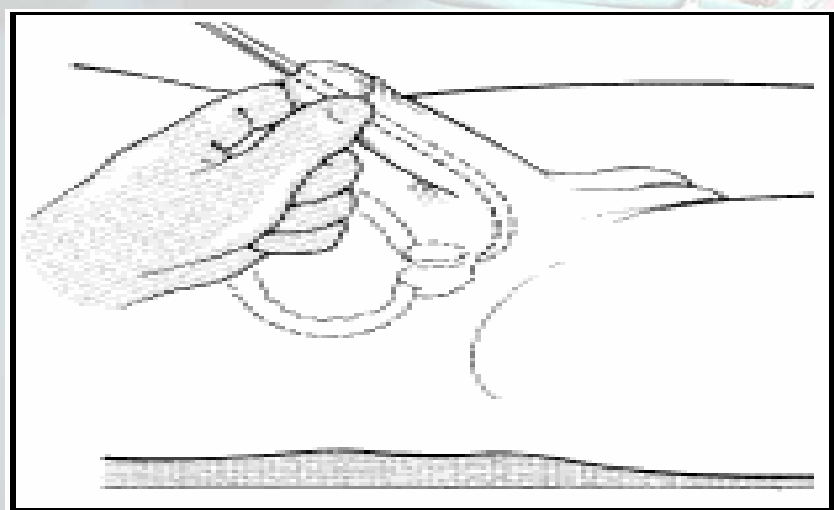


Figure 9.25

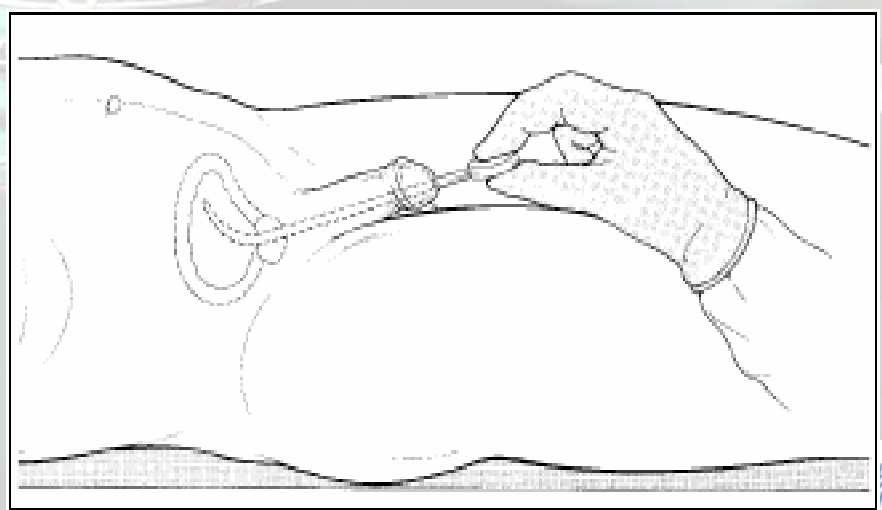


Figure 9.26



9.2 THE MALE URETHRA

Urethral Stricture

- Possible complications
 - Trauma-bleeding or creation of a false passage
 - Bacteraemia
 - Septicaemia and septic shock.
- Minimize complications by asepsis and the use of antibiotics.



9.2

THE MALE URETHRA

Male Circumcision

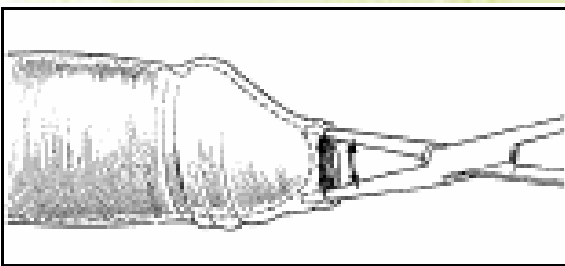


Figure 9.27

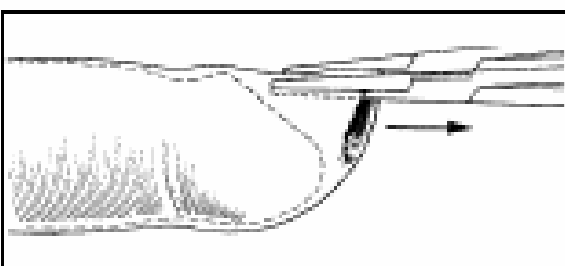


Figure 9.28

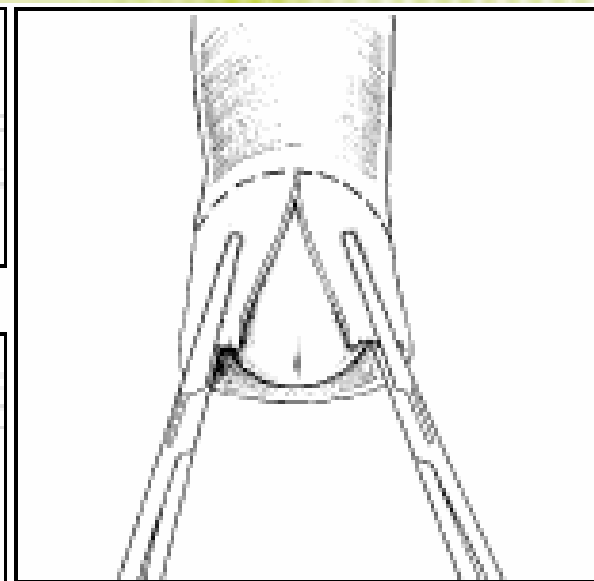


Figure 9.29

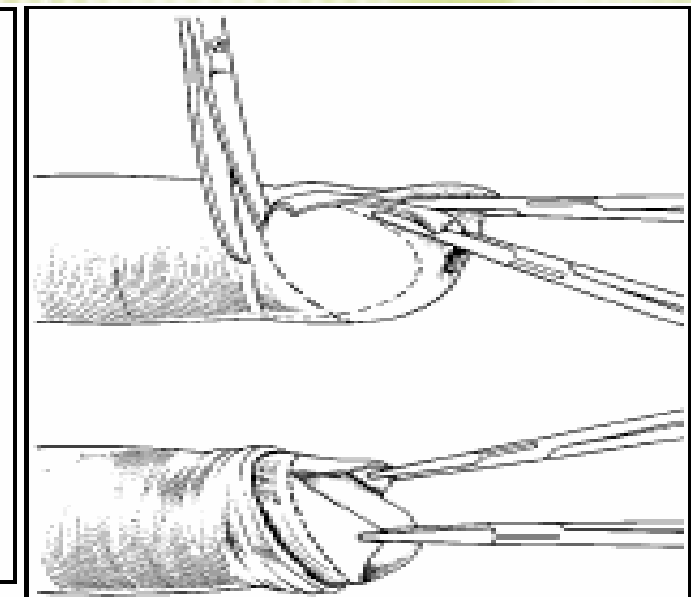


Figure 9.30

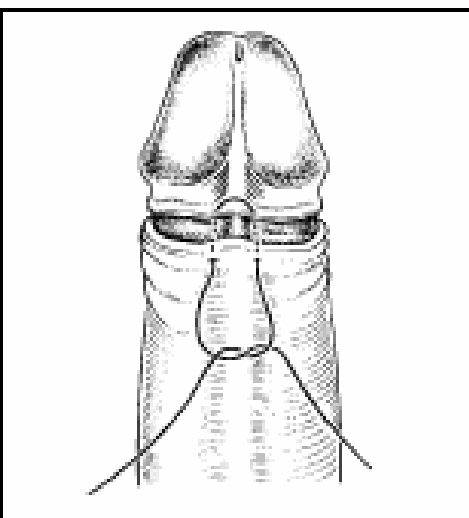


Figure 9.31

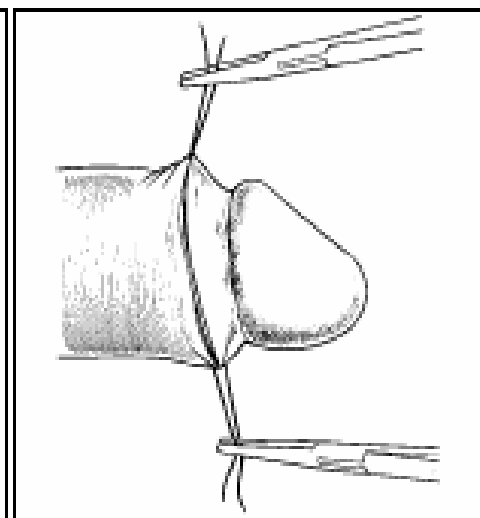


Figure 9.32

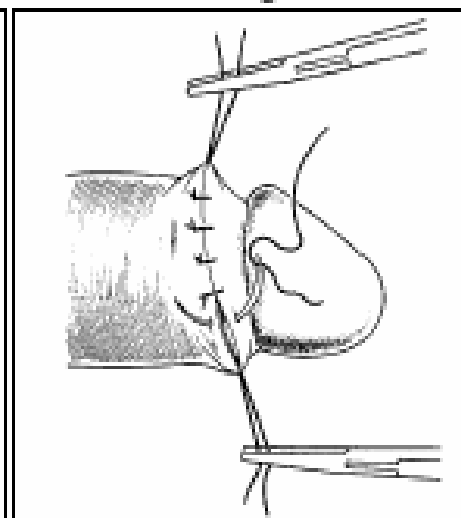


Figure 9.33

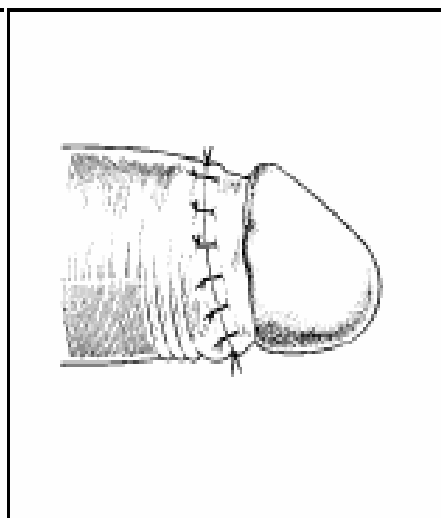


Figure 9.34



9.2 THE MALE URETHRA

Paraphimosis

- Occurs most commonly in children.
- Diagnose it by recognizing a retracted, swollen and painful foreskin. The glans penis is visible, and is surrounded by an oedematous ring with a proximal constricting ring

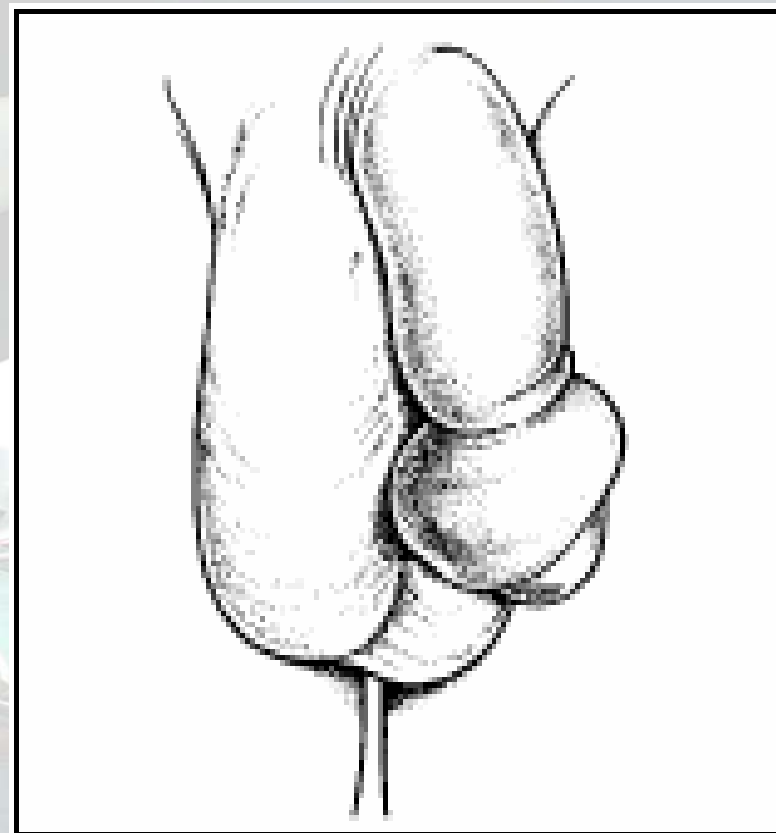


Figure 9.35

9.2 THE MALE URETHRA

- Paraphimosis should be treated urgently with manual reduction of the foreskin or dorsal slit
- Phimosis is prevented by reduction of the foreskin and cleansing of the glans penis on a regular basis
- Phimosis may be treated definitively by circumcision or with a dorsal slit, if necessary.



9.2 THE MALE URETHRA

Reduction of the Foreskin

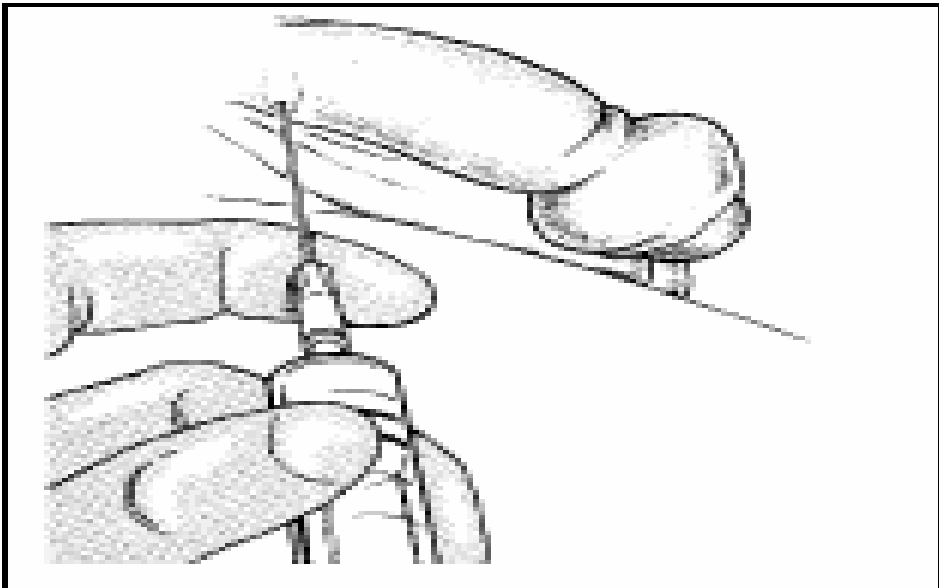


Figure 9.36

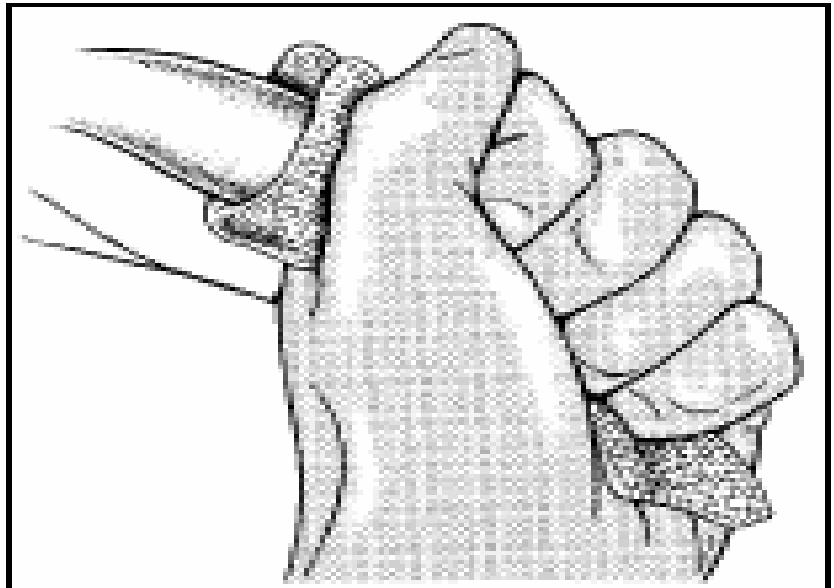


Figure 9.37

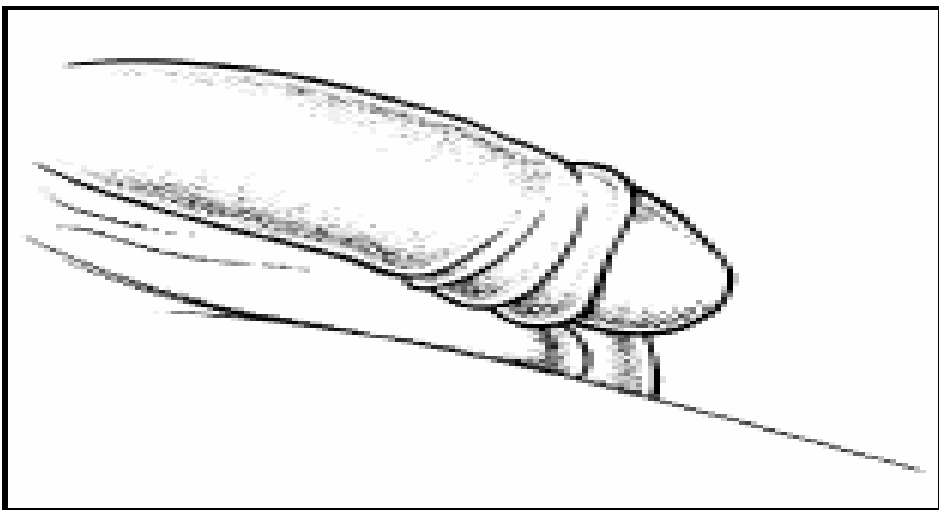


Figure 9.38

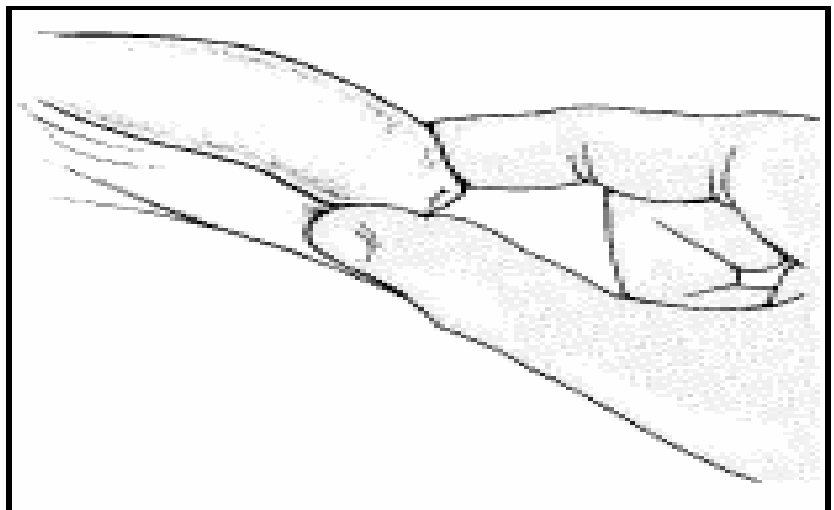


Figure 9.39



9.2 THE MALE URETHRA

- **Phimosis and paraphimosis are definitively treated with circumcision, but can be treated with a dorsal slit of the foreskin.**
- **Dorsal slit can be performed with direct infiltration of the foreskin with xylocaine 1% without epinephrine (adrenaline)**
- **Clamp the foreskin with two artery forceps and make an incision between them**

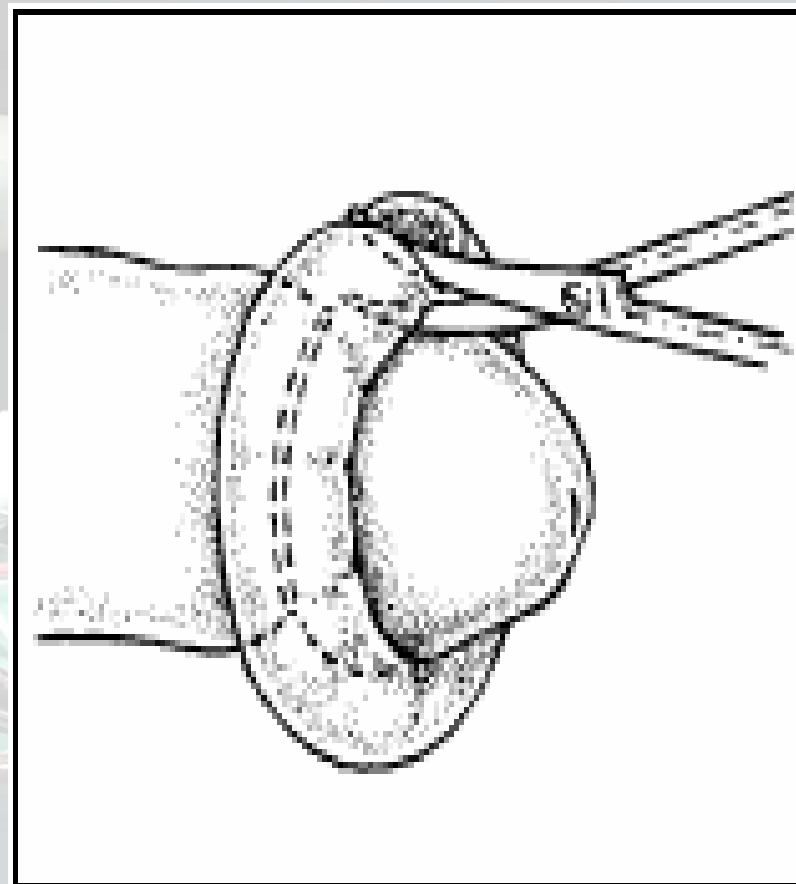


Figure 9.40



9.2 THE MALE URETHRA

torsion of the testis

- In torsion, the testicle can become gangrenous in 4 hours; treatment is thus an emergency
- The non-affected side should be fixed at the same time as the subsequent incidence of torsion on the opposite side is high
- When the testis is dead, orchidectomy should be performed to protect the other testis from loss due to autoimmune disease
- One testicle is enough for normal fertility.



9.2 THE MALE URETHRA

Scrotal hydrocoele

Scrotal hydrocoele is an abnormal accumulation of fluid in the tunica vaginalis sac

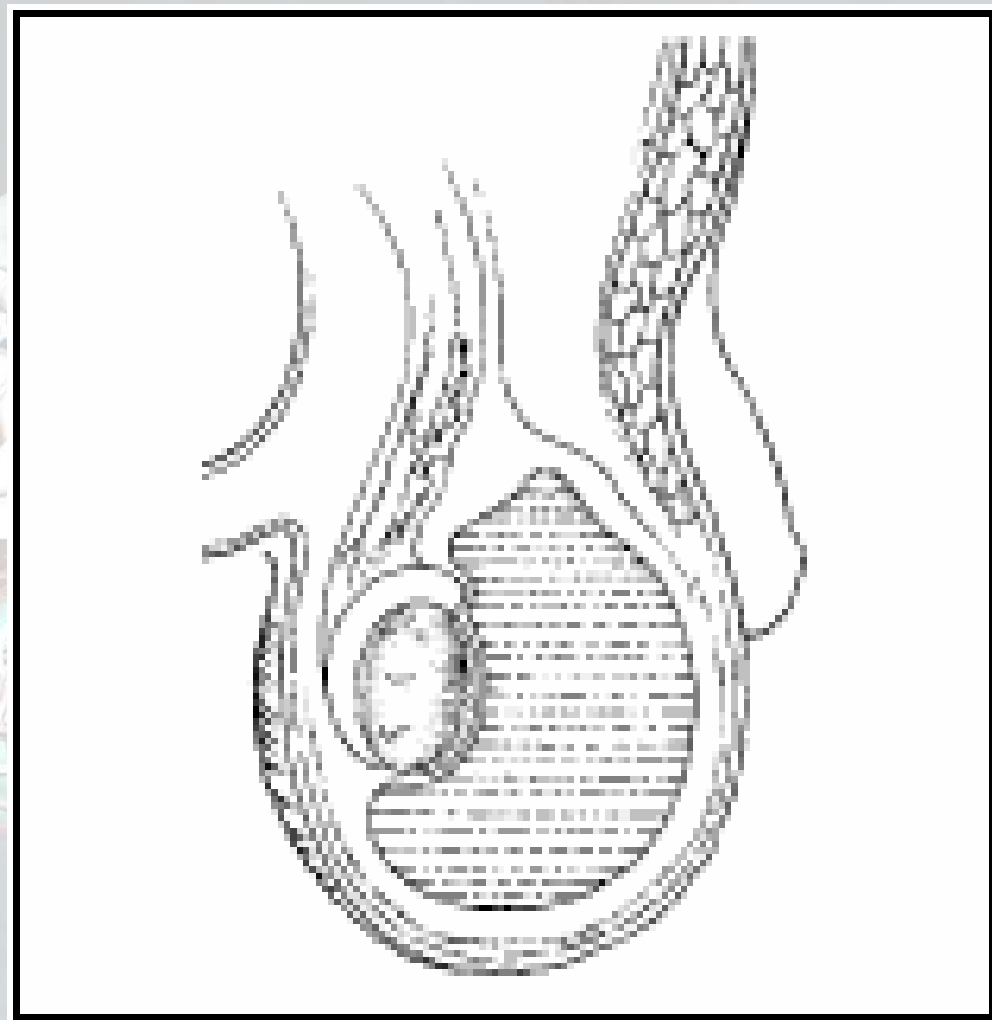


Figure 9.41

9.2 THE MALE URETHRA

Scrotal hydrocoele

- A hydrocoele is differentiated from hernia in that it:
 - Does not extend above the inguinal ligament
 - Transilluminates
 - Does not reduce
 - Does not transmit a cough impulse



9.2 THE MALE URETHRA

Scrotal hydrocoele

- In children, the hydrocoele often communicates with the peritoneal cavity; it is a variation of hernia and is managed as a hernia
- Non-communicating hydrocoeles in children under the age of 1 year often resolve without intervention
- The surgical management of adult hydrocoele is not appropriate for children.



9.2 THE MALE URETHRA

Scrotal hydrocoele Treatment

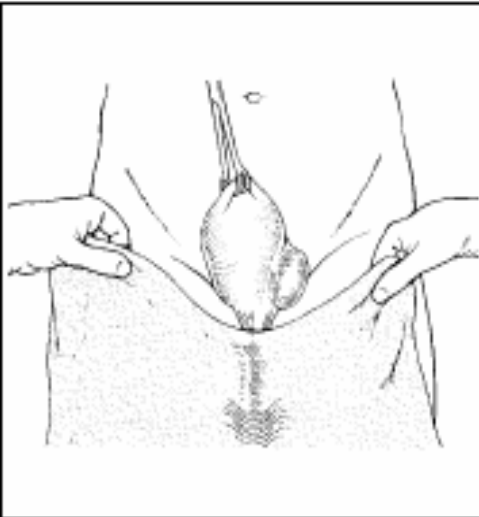


Figure 9.42

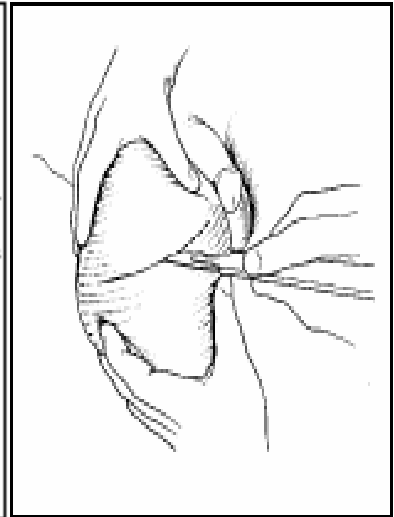


Figure 9.43

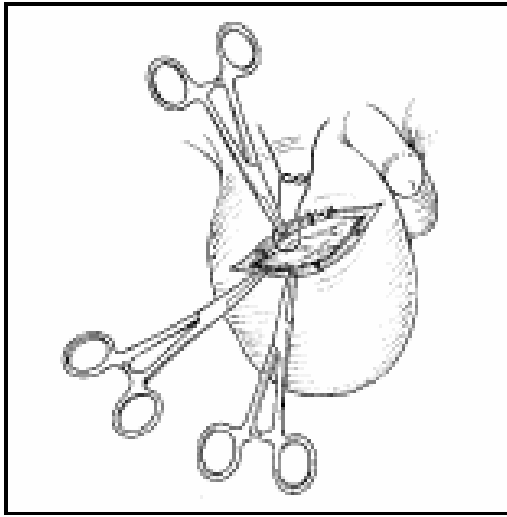


Figure 9.44

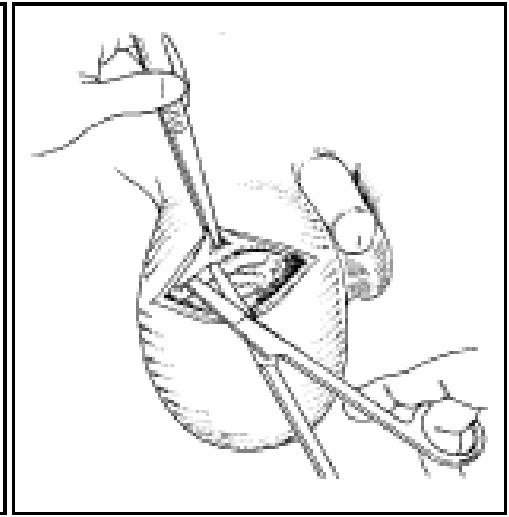


Figure 9.45

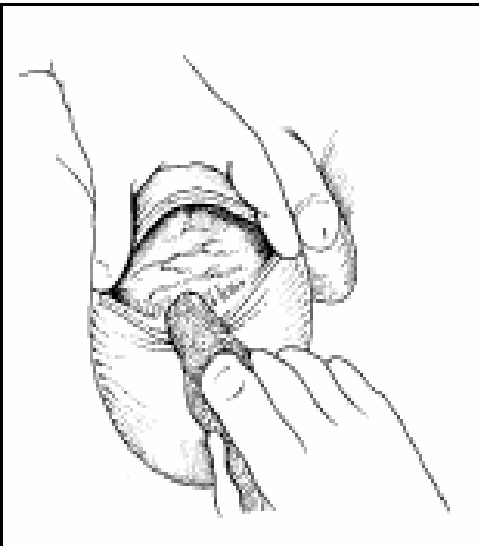


Figure 9.46

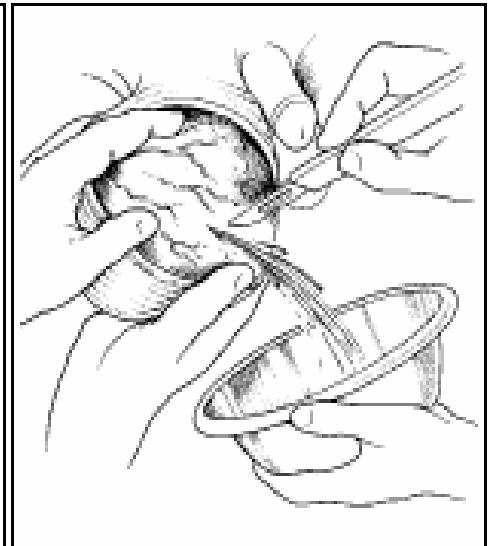


Figure 9.47

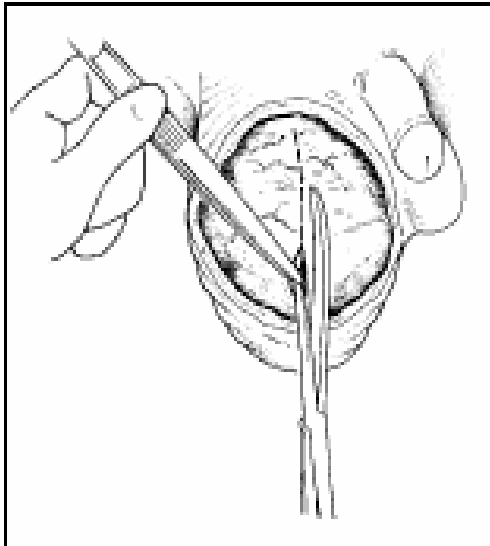


Figure 9.48

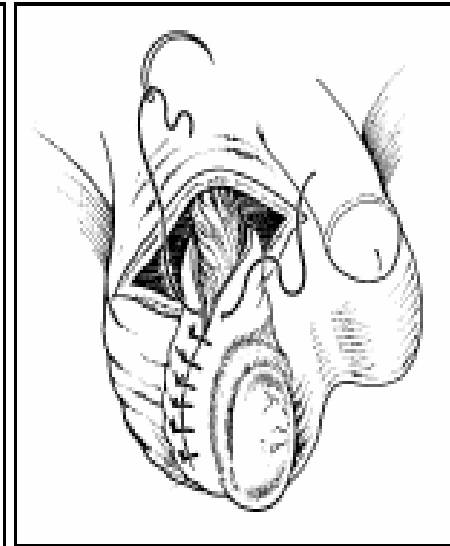


Figure 9.49

9.2

THE MALE URETHRA

Vasectomy

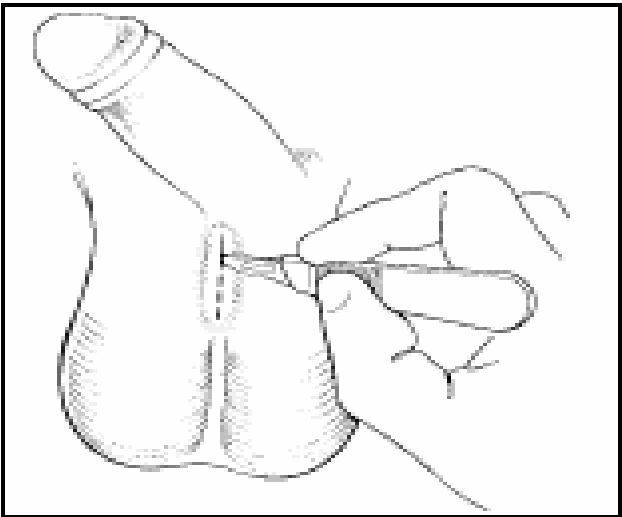


Figure 9.54

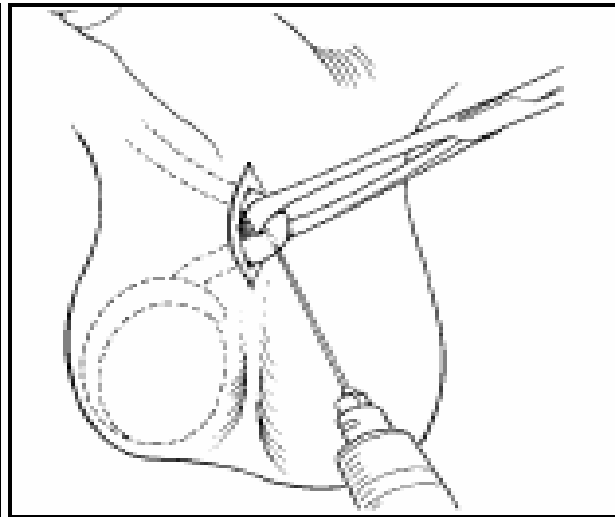


Figure 9.55

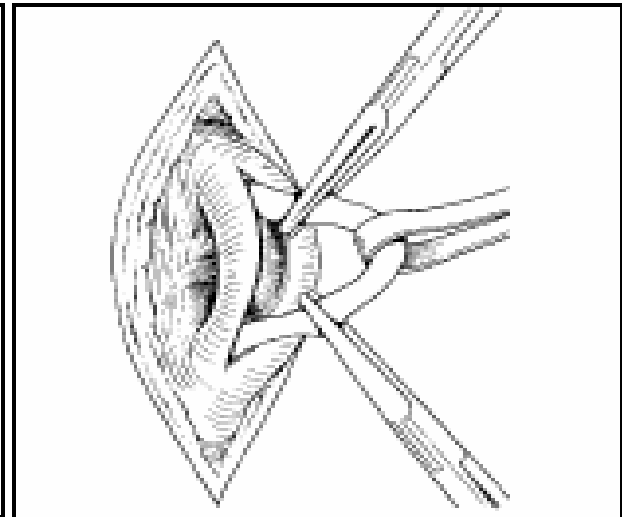


Figure 9.56

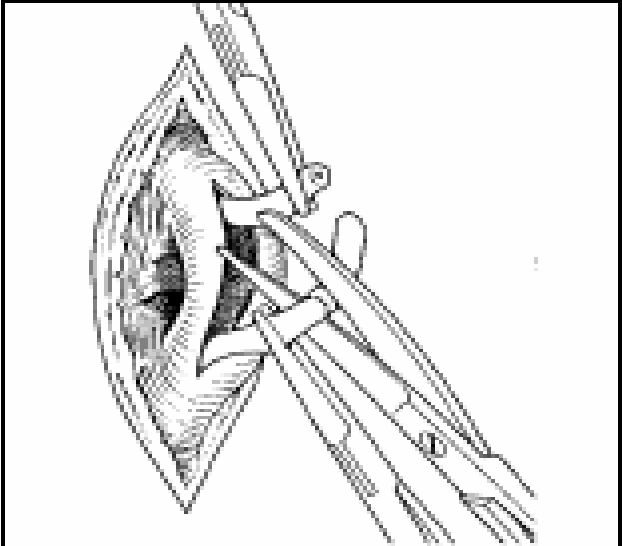


Figure 9.57

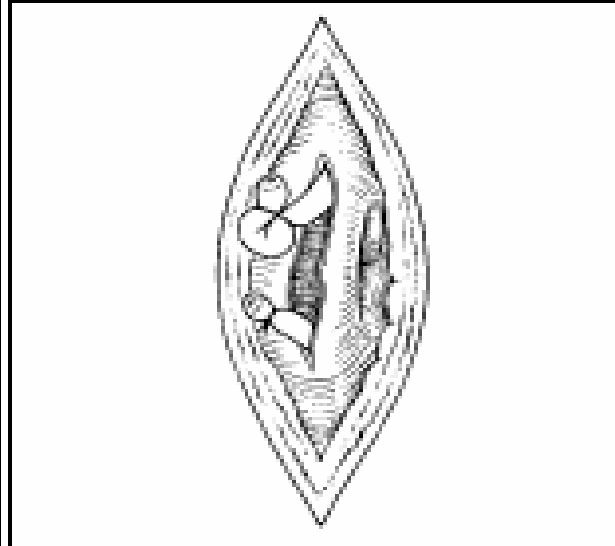


Figure 9.58

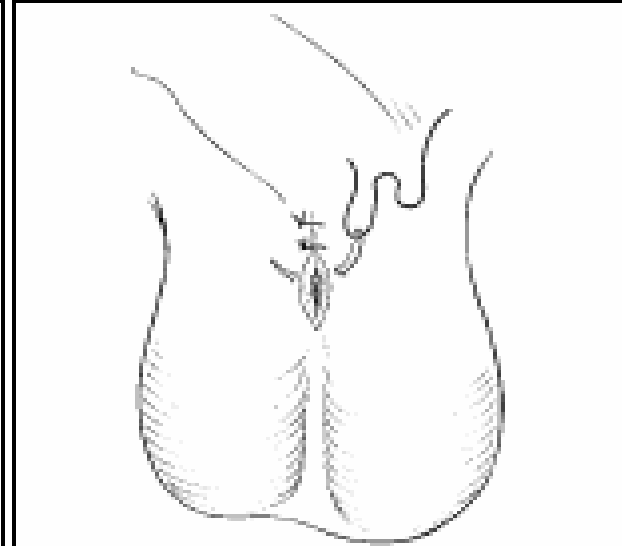


Figure 9.59



9.3 THE PERINEUM

Female genital mutilation

- There is no health indication for female genital mutilation
- Acute complications include:
 - Haemorrhage
 - Shock
 - Urinary retention
 - Damage to the urethra and anus
 - Cellulitis
 - Abscesses



9.3 THE PERINEUM

Female genital mutilation

- **Chronic complications include:**
 - Sexual dysfunction
 - Psychological disturbance
 - Urinary obstruction
 - Keloids
 - Large epidermal inclusion cysts
 - Difficult micturition
 - Vaginal stenosis, which can cause obstructed labour, often complicated by vesical or rectal vaginal fistulae.



9.3 THE PERINEUM

PERINEAL ABSCESSSES

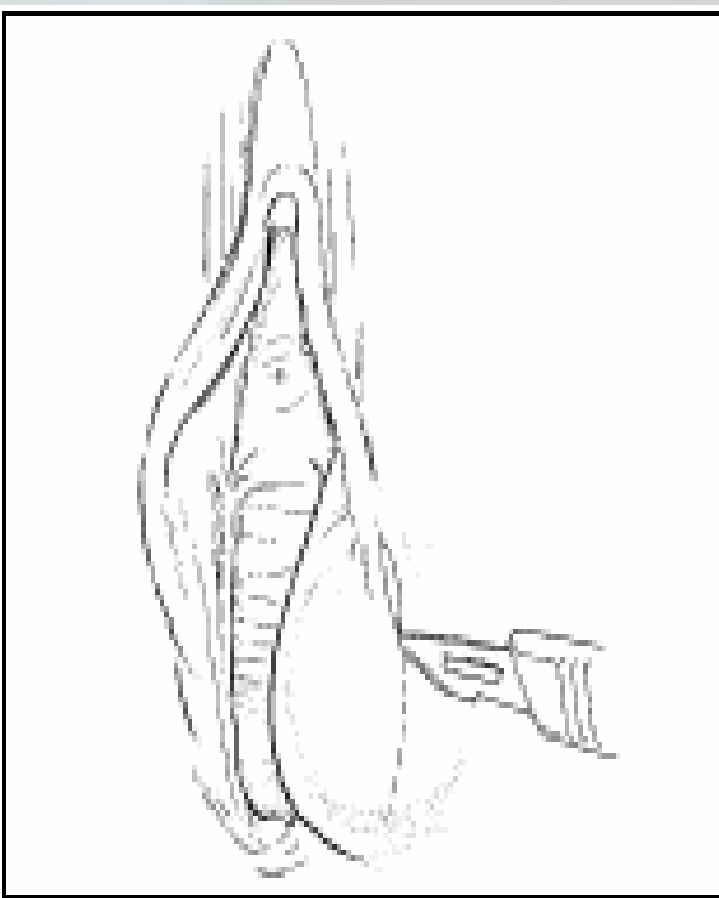

Figure 9.60

HAEMATOCOLPOS

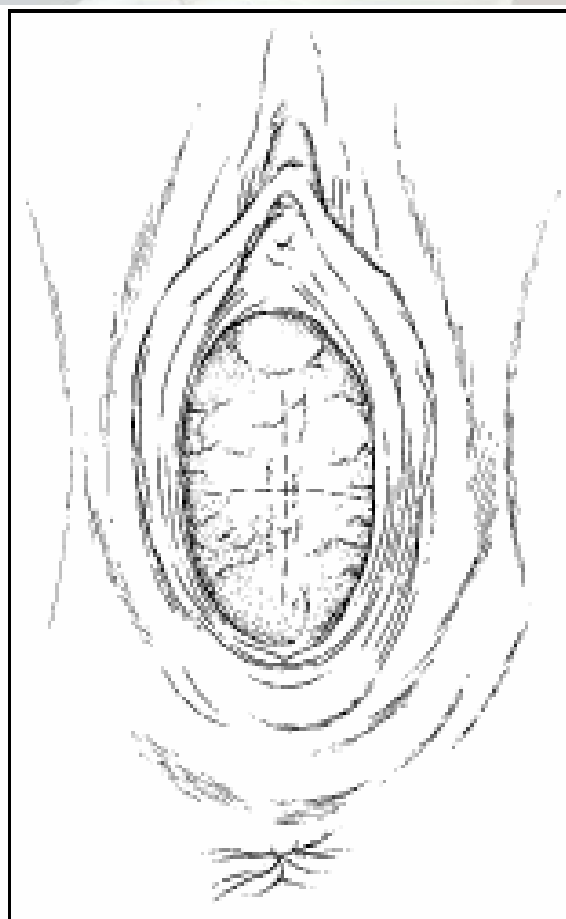


Figure 9.61

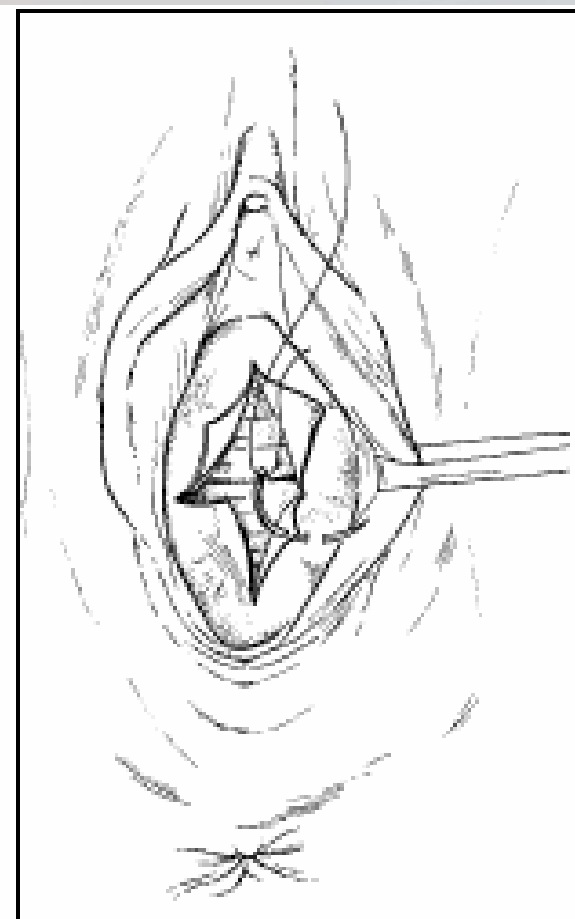


Figure 9.62