



WHO/CDS/CSR/EPH/2001.5

The Revision of the Surveillance Case Definition for Variant Creutzfeldt-Jakob Disease (vCJD)

Report of a WHO consultation

Edinburgh, United Kingdom 17 May 2001

World Health Organization

Department of Communicable Disease,
Surveillance and Response

This document has been downloaded from the WHO/CSR Web site. The original cover pages and lists of participants are not included. See <http://www.who.int/emc> for more information.

© World Health Organization

This document is not a formal publication of the World Health Organization (WHO), and all rights are reserved by the Organization. The document may, however, be freely reviewed, abstracted, reproduced and translated, in part or in whole, but not for sale nor for use in conjunction with commercial purposes.

The views expressed in documents by named authors are solely the responsibility of those authors. The mention of specific companies or specific manufacturers' products does not imply that they are endorsed or recommended by the World Health Organization in preference to others of a similar nature that are not mentioned.

The Revision of the Surveillance Case Definition for Variant Creutzfeldt-Jakob Disease (vCJD)

Report of a WHO consultation

Edinburgh, United Kingdom
17 May 2001



WORLD HEALTH ORGANIZATION
Department of Communicable Disease Surveillance and Response

© World Health Organization 2002

All rights reserved. Publications of the World Health Organization can be obtained from Marketing and Dissemination, World Health Organization, 20 Avenue Appia, 1211 Geneva 27, Switzerland (tel: +41 22 791 2476; fax: +41 22 791 4857; email: bookorders@who.int). Requests for permission to reproduce or translate WHO publications - whether for sale or for noncommercial distribution - should be addressed to Publications, at the above address (fax: +41 22 791 4806; email: permissions@who.int).

The designations employed and the presentation of the material in this publication do not imply the expression of any opinion whatsoever on the part of the World Health Organization concerning the legal status of any country, territory, city or area or of its authorities, or concerning the delimitation of its frontiers or boundaries. Dotted lines on maps represent approximate border lines for which there may not yet be full agreement.

The mention of specific companies or of certain manufacturers' products does not imply that they are endorsed or recommended by the World Health Organization in preference to others of a similar nature that are not mentioned. Errors and omissions excepted, the names of proprietary products are distinguished by initial capital letters.

The World Health Organization does not warrant that the information contained in this publication is complete and correct and shall not be liable for any damages incurred as a result of its use.

Contents

Abbreviations used	1
Introduction	2
Background.....	3
Key elements in the diagnosis of vCJD.....	4
I. Suspect vCJD: clinical diagnosis.....	4
II. Probable vCJD	8
The role of EEG in the diagnosis of vCJD.....	8
The role of 14-3-3 in the diagnosis of vCJD.....	8
Number of samples positive 14-3-3 /total samples investigated.....	9
The role of magnetic resonance imaging (MRI) in the diagnosis of vCJD	9
The role of tonsil biopsy and lymphoreticular tissues in the diagnosis of vCJD.....	10
III. Definite vCJD.....	12
The role of neuropathology in the diagnosis of vCJD	12
Suggested approaches to post-mortem examination	13
Western blot analysis of PrP isotype in the diagnosis of vCJD	13
Handling of instruments used to diagnose vCJD	14
Annex I Case definition for vCJD	15
Annex II Agenda for the consultation	16
Annex III List of scientific presentations to the consultation.....	17
Annex IV Participants	18
Annex V Pathological characteristics of vCJD (from 1998 WHO Consultation).....	20
Annex VI EEG criteria for sporadic CJD.....	21
Annex VII List of reference centres	22
Annex VIII Clinical features of variant CJD, sporadic CJD and suspect vCJD cases with an alternative final diagnosis.....	23
Annex IX Selected references	24
Web sites	29

Abbreviations used

TSE	Transmissible spongiform encephalopathy
CJD	Creutzfeldt-Jakob disease
sCJD	sporadic Creutzfeldt-Jakob disease
vCJD	variant Creutzfeldt-Jakob disease
BSE	Bovine spongiform encephalopathy
PrP	Prion protein
PrP ^{Sc}	Scrapie, amyloid forming isoform of the prion protein
PrP ^C	Cellular isoform of the prion protein
EEG	Electroencephalogram
MRI	Magnetic resonance imaging

Introduction

In 1998 WHO developed a case definition for vCJD, as well as for sporadic, iatrogenic and familial CJD¹. At that time only 34 vCJD cases had been reported. Since then, experience in the diagnosis of the disease has increased. Additionally, certain diagnostic methods (e.g. magnetic resonance imaging, tonsil biopsy) have been proved to be valuable tools in the diagnosis of vCJD. Finally, the clinical case definition in the UK has been revised to permit the diagnosis of vCJD in the absence of neuropathology. The result was a need for WHO to review its existing case definition for vCJD. To this end, WHO convened a Consultation on the Revision of the Surveillance Case Definition for variant Creutzfeldt-Jakob Disease (vCJD), which was held in Edinburgh, United Kingdom, on 17 May 2001.

Dr Maura Ricketts from the WHO department of Communicable Disease Surveillance and Response opened the meeting. She highlighted the need to revise the WHO case definition of vCJD in view of the improved knowledge regarding the diagnosis of vCJD. She emphasized the need to formulate criteria for suspect cases of vCJD for regions of the world that may have restricted access to investigations such as EEG, MRI and neuropathology.

The following document is based upon the scientific presentations (see Agenda, Annex II) and discussions during the consultation. Note that the recommendations of this consultation refer to vCJD, and not sporadic CJD (sCJD) and that the goal of the consultation is to improve surveillance. The organization of the document reflects the clinical hierarchy used in the diagnosis of human diseases – symptoms, signs in clinical examination, followed by investigations of increasing invasiveness ending in neuropathology. The addition of each successive class of information increases the likelihood that the correct diagnosis is being made, as seen in the revised case definition.

The principal recommendation of the consultation was that WHO adopt an amended version of the case definition currently used in the UK and by the European Union BioMed 2 Surveillance Projects (Annex I). The consultation recommended that one of the footnotes should be augmented to clarify the role of tonsil biopsy, and the clinical criteria be amended to exclude familial CJD. A footnote to clarify the definition of a diagnostic MRI has been added.

This report has been prepared by the WHO secretariat (Drs Maura Ricketts, Paola Pergami) in close collaboration with the Consultation's chair Dr Robert Will, speakers (particularly Drs Don Collie, James Ironside and Richard Knight, see Annex III) and rapporteurs (Drs Martin Zeidler and Hester Ward). It is based on the scientific presentations of the speakers, and it contains the conclusions and recommendations of the consultation.

¹ WHO Consultation on the Global Surveillance, Diagnosis and Therapy of Human Transmissible Spongiform Encephalopathies. 9-11 February 1998, Geneva, Switzerland, WHO/EMC/ZDI/98.9

Background

Creutzfeldt-Jakob disease (CJD) was first described in the 1920s. The disease is part of a group of diseases called transmissible spongiform encephalopathies (TSEs) or prion diseases that occur in humans or animals. The diseases have a prolonged incubation period and are characterized by an invariably fatal degeneration of the nervous system. Sporadic CJD (sCJD) is the most common of the human TSEs representing about 85% of CJD cases. The disease is rare, with an annual incidence across the world of 0.5 to 1.0 cases per million population. The average age of onset of sCJD is between 55 and 75 years and it has no known cause. About 15% of CJD cases are familial and are caused by genetic mutations. In addition, CJD has been transmitted as a result of medical treatments such as human pituitary derived growth hormone injections, dura mater and corneal tissue transplants, and brain surgery involving contaminated instruments. Post-mortem neuropathological examination shows spongiform degeneration, neuronal loss, gliosis, and accumulation of the abnormal isoform of the prion protein. The precise nature of the agent responsible for CJD is not fully understood, but the most likely theory points to an abnormal isoform (prion protein PrP^{Sc}) of a protein that is normally expressed in the brain (the cellular isoform of the prion protein, PrP^C). It is generally accepted that the difference between PrP^C and PrP^{Sc} is purely conformational. The abnormal protein accumulates and there is a massive destruction of the brain, which assumes the characteristic spongy appearance. The clinical symptoms of sCJD include cognitive impairment leading to dementia, a cerebellar syndrome with gait and limb ataxia, and myoclonus in the late stages.

In March 1996 a new variant of CJD (vCJD) was identified in the United Kingdom (UK). A causal link between vCJD and bovine spongiform encephalopathy (BSE) in cattle has been hypothesized, and there is now overwhelming epidemiological, neuropathological and experimental evidence that the agents causing BSE and vCJD are the same. The most plausible route of exposure is via BSE contaminated food.

As of May 2001, 104 vCJD cases had been reported; 100 in the United Kingdom, three in France and one in the Republic of Ireland. A consistent upward trend in the number of reports in the UK has been observed, but it is still too soon to tell whether this increase will be sustained, or what the eventual number of vCJD cases will be. Countries without reported cases of either vCJD or BSE may also have been exposed to the BSE agent as a result of importation of cattle or cattle-derived products from BSE-affected countries. As a result, the possibility of a significant and geographically diverse vCJD epidemic occurring over the next few decades cannot be dismissed. WHO has responded to this concern through its activities to promote global surveillance of CJD and by holding consultations on various issues related to TSEs and public health.

Key elements in the diagnosis of vCJD

The following section is organized to follow the new vCJD case definition presented in Annex I.

I. Suspect vCJD: clinical diagnosis

The clinical picture of vCJD is relatively distinct from that of the disease with which it is most likely to be confused – sCJD. The presenting symptoms are usually non-specific and predominantly psychiatric (anxiety, depression, brief delusions and sometimes withdrawal and progressive behavioural changes). Sensory symptoms (e.g. dysaesthesiae in the limbs and/or face, sensations of cold, pain) may accompany the psychiatric illness or, as in 50% of cases, develop later. The predominant psychiatric picture may result in a delay between the onset of symptoms and diagnosis. However, other neurologic features, including cerebellar signs and involuntary movements (particularly myoclonus, chorea, dystonia) develop. Memory disturbances appear and, as with sCJD, the disorder progresses to severe cognitive impairment and immobility. As of May 2001 there is no curative treatment, and death remains inevitable.

Compared to sCJD, vCJD is characterized by a younger age of onset (mean 27 years, versus mean 66 years in sCJD) and by a longer duration of illness (median 13 months, range 6 – 39, versus 4.5 months in sCJD).

Clinical examination remains the first, essential step in the differential diagnosis of vCJD. Table 1 lists the outcome of 34 cases of suspected vCJD that were eventually, because of clinical features, seen to not be vCJD. It is noteworthy that nearly half of such cases improved and that others were found to be suffering from potentially treatable conditions. Therefore, possible differential diagnoses should always be kept in mind in order to avoid the risk of not correctly identifying another, treatable disease.

Recovered		4
Improved		15
Alternative clinical diagnosis		9
Peripheral neuropathy	2	
Alzheimer's disease	1	
Vitamin B12 deficiency	1	
Cerebrovascular disease	1	
Wilson's disease	1	
Possible encephalitis lethargica	1	
Corticostriatonigral degeneration	1	
Cerebral vasculitis	1	
Stable		6

Table 1. Outcome in suspect vCJD cases classified as clinically unlikely (n=34)

Table 2 lists the outcome of 30 cases initially suspected to have vCJD but reclassified as other diseases after neuropathology. The most common pathological differential diagnoses of vCJD are sCJD and Alzheimer's disease.

Post-mortem neuropathology	
Sporadic CJD	8
Alzheimer's disease	5
Encephalitis	2
Cerebrovascular disease	1
Cerebral vasculitis	1
Limbic encephalitis	1
Multi-system degeneration	1
Possible metabolic disorder	1
Post-viral encephalopathy	1
Progressive multifocal leuco-encephalopathy	1
Wilson's disease	1
Multiple sclerosis	1
Normal brain	1
Biopsy	
Cerebral vasculitis	2
Sporadic CJD	1
Normal brain	1
Genetic testing	
Huntington's disease	1

Table 2. Outcome of neuropathology in cases suspected to have vCJD (n=30)

Countries with limited access to MRI, neuropathology and other investigative tools may not be able to categorize *Probable* or *Definite* vCJD cases. Therefore, the case definition allows for classification of suspected cases as *Possible* based on a constellation of symptoms, signs and the absence of an EEG pathognomonic for sCJD. However, in general, over 60% of suspect cases referred to the UK CJD Surveillance Unit for the investigation of vCJD are found not to have vCJD. The consultation considered ways of modifying the clinical criteria to increase specificity by including several additional clinical characteristics. Those countries seeking to restrict investigations to suspect cases with a higher likelihood of vCJD should consider the following:

1. Age

All but nine vCJD cases identified to date have been under 40 years of age at the time of diagnosis. As conditions causing dementia (including sporadic CJD - see Figure 1) are relatively uncommon in this age group it would seem appropriate, particularly in countries with limited resources, to target surveillance to suspect cases less than 40 years old.

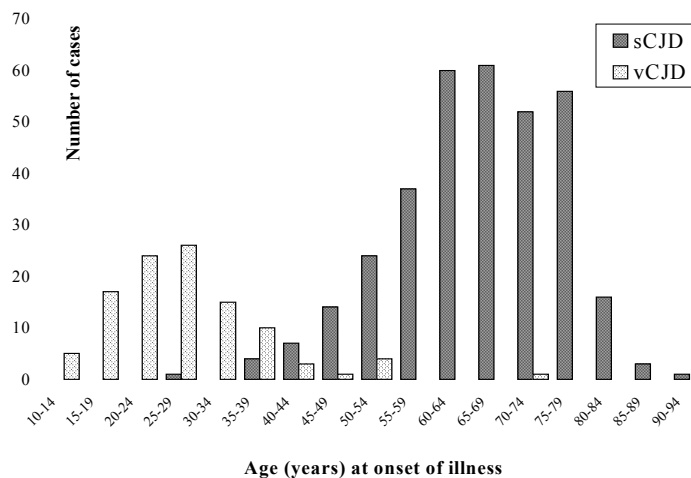


Figure 1. Age of onset for sporadic and variant CJD

2. Duration of illness

All cases of vCJD have had an illness duration of six months or longer and the vast majority (>90%) died within two years of the onset of symptoms. Therefore, it would be appropriate to limit suspect cases to those with an illness duration that exceeds six months and is less than two years.

An inverse relation between duration of illness and age at onset is observed. Therefore, in older patients the relative short duration of illness can help distinguish CJD from other forms of dementia but it cannot discriminate between vCJD and sCJD.

3. Clinical symptoms

Appendix VIII shows the percentage of various clinical features in vCJD, sCJD and patients initially suspected to have vCJD but with an alternative final diagnosis. There is no single clinical characteristic that clearly distinguishes these groups, but certain features may be helpful discriminators. In particular, persistent sensory symptoms, early psychiatric symptoms, chorea and upgaze paresis are much more common in vCJD, whereas early forgetfulness and ataxia are relatively uncommon.

Most neurological symptoms develop later in the course of illness and the great majority of patients are referred to a neurologist within a few months. For this reason, cases with progressive neuropsychiatric disorder should be investigated and followed up. The longer evolution of vCJD requires repeated examinations in order to follow the development of new symptoms. vCJD cannot be diagnosed based on one single observation.

4. Family history

To exclude patients with hereditary neurodegenerative disorders, anyone suspected of vCJD should not have a family history of a similar condition. Therefore, an accurate family history is essential. Familial forms can be excluded by genetic testing for mutations of the PrP gene. If PrP gene analysis cannot be performed, blood for genetic investigations can be sent to the WHO reference centres listed in Annex VII.

5. Exclusion of sporadic CJD

Differentiation of sCJD from vCJD may be difficult as the clinical phenotype may overlap. Table 3 offers some criteria that may discriminate between vCJD and sCJD.

	Suggestive of vCJD	Suggestive of sCJD
Early clinical features		
Psychiatric symptoms	Present	Absent
Sensory disturbances	Present	Absent
Rapid clinical progression	Absent	Present
Age	< 40 years	> 40 years ²
Duration of illness	>12 months	< 6 months

Table 3. Clinical criteria more suggestive of vCJD than sCJD

6. Exclusion of iatrogenic CJD

Exclusion of iatrogenic CJD (e.g. no exposure to human pituitary-derived products, not a recipient of dural or corneal grafts, exclusion of neurosurgical exposure) is required in every suspected case.

In summary, clinical criteria, if strictly applied, can suggest vCJD. These criteria are defined based on the observation of vCJD cases in the UK. It is notable that all vCJD cases tested to date are methionine homozygotes at codon 129 of the prion protein gene. For this reason the possibility of a different phenotype in different genetic subgroups remains. Furthermore, the possibility that genetic factors in other populations may influence the phenotype of human infection by the BSE agent cannot be dismissed (although it was noted that the clinical features of the vCJD cases from France and the Republic of Ireland did not appear to be different from the UK cases). Additionally, since the large majority of patients described to date are of a young age, it is not known if the disease will be clinically different in older age groups - although it was noted that the clinical features of a recent vCJD case in the UK who died at age 74 were similar to those of the other younger patients. Those exposed to BSE through different routes of exposure or some peculiarity in diet might also present with a distinct phenotype. Finally, because disease duration might influence the clinical features, anything affecting disease duration (i.e. age) could alter the clinical features.

The possibility of an alternative diagnosis must always be considered in order to avoid mistaking vCJD for other treatable diseases. At the time of the consultation, no therapeutic intervention altered the clinical course and therefore, sustained improvement (over a period of months) or recovery excludes the diagnosis of vCJD.

² Patients over 40 years of age with the symptoms of a human TSE are more likely to be sporadic CJD cases.

II. Probable vCJD

The role of EEG in the diagnosis of vCJD

A periodic EEG recording is considered one of the most characteristic findings in sCJD (see Annex VI). The presence of periodic sharp-wave complexes is reported to have a sensitivity of 67% and a specificity of 86% for sCJD.

However, the characteristic periodic changes seen in sCJD are not a feature of vCJD. In the 104 cases of vCJD described as of May 2001, no changes considered typical of sCJD were seen even if the EEG recording was performed late in the course of illness (i.e. over six months after the onset, over 66 % of duration of illness and even within two days of death in one case).

EEG recordings in vCJD usually show non-specific slow-wave abnormalities but some patients have had normal tracings, even in the relatively later phases of the disease when clinical signs and cognitive impairment were present. However, a normal EEG is in keeping with the diagnosis of vCJD especially in the early stages of illness, while a periodic record suggests sCJD. Nevertheless, it is necessary to remember that even in sCJD the EEG can be non-diagnostic for CJD. An abnormal EEG can be of some help in differentiating between CJD and pure psychiatric disorders.

The role of 14-3-3 in the diagnosis of vCJD

Cerebrospinal fluid (CSF) studies are important in the investigation of patients with suspected vCJD. A raised total protein (typically 0.5 –1.0g/L, although higher values have been reported) may be seen in about one third of cases, however, this test is non-diagnostic for vCJD. CSF pleiocytosis or low glucose concentrations are not features of vCJD and are suggestive of an alternative diagnosis.

14-3-3 has been examined as a laboratory marker of CJD. 14-3-3 is a neuronal protein involved in cell signaling and is present in high concentrations within the central nervous system. It may be released into the CSF in a number of neurological and pathological conditions affecting neuronal integrity. Therefore, its presence in the CSF is not specific for CJD. However, in the appropriate clinical context, the detection of 14-3-3 in the cerebrospinal fluid (CSF) has a high degree of sensitivity and specificity for the diagnosis of sCJD. The accuracy of this test has led the World Health Organization (WHO) and the European Union's Programme for the Surveillance of CJD to revise their clinical criteria for the diagnosis of sCJD to include a positive 14-3-3. In patients who have a progressive dementia of less than two years' duration, a positive CSF test for 14-3-3 protein is considered to have a diagnostic weight equal to that of specific EEG findings in sCJD. Helpfully, the protein seems to be stable even at room temperature for prolonged periods and CSF samples can be easily sent by mail to reference centres for testing.

In the appropriate clinical context 14-3-3 has a high specificity in distinguishing vCJD and sCJD from other dementing illnesses, but in vCJD it is less sensitive than in sCJD. For example, in the UK CJD Surveillance Unit, the sensitivity of CSF 14-3-3 detection in the diagnosis of vCJD has been reported to be between 50-60% and its specificity appears to be up to 94% (Table 4).

Classification according to UK surveillance criteria	Number of samples positive 14-3-3 /total samples investigated
Definite vCJD	28/53
Probable vCJD	2/15
Not CJD	3/49
sensitivity	53%
specificity	94%

Table 4. Sensitivity and specificity of 14-3-3 in vCJD in qualified clinical setting (i.e. patients referred to the CJD unit for assessment)

Consequently, the finding of a positive CSF 14-3-3 in a patient with clinical features of vCJD is supportive, but not absolutely confirmatory, of the diagnosis, while a negative result cannot be used to exclude it. At present, although 14-3-3 is potentially clinically useful, it is not part of the internationally accepted diagnostic clinical criteria for vCJD. There is evidence to suggest that a positive CSF 14-3-3 is more likely to be found in the mid-stage of the disease; however this finding should not be used to determine the timing of lumbar puncture as CSF 14-3-3 has been detected at all points in the disease process.

As there is no difference between the electrophoretic pattern of the CSF 14-3-3 found in vCJD and that found in sCJD (although lower concentrations tend to be found in vCJD) CSF 14-3-3 cannot be used to distinguish between the two forms. This is particularly relevant as sCJD is the main differential diagnosis of vCJD. Finally, in some other neurological diseases CSF may be positive for 14-3-3 protein.

The analysis of CSF 14-3-3 requires specialized technical and interpretative skills and it is strongly recommended that samples are sent to the centres listed in Annex VII for analysis.

At present no other brain-specific proteins found in the CSF (i.g. S100b, NSE) should be used in the routine diagnostic investigation of patients with vCJD. However CSF tau protein may be useful and current studies are under way evaluating its diagnostic value.

The role of magnetic resonance imaging (MRI) in the diagnosis of vCJD

A characteristic distribution of symmetrical hyperintensity (relative to the cortical and other deep grey matter nuclei signal intensity) of the pulvinar nucleus (posterior nucleus) of the thalamus is seen on axial images in the majority of patients with confirmed vCJD. These changes have been named the ‘pulvinar sign’ and this sign is 90% sensitive for the diagnosis of vCJD. In the appropriate group of patients, (i.e. those with clinical features consistent with vCJD), the specificity of the pulvinar sign is over 95%. The pulvinar sign is currently the best non-invasive *in vivo* diagnostic test of vCJD.

The changes of the pulvinar sign are best seen on axial images but may be seen in other planes. The pulvinar sign of vCJD has been described on T2-weighted images, proton density-weighted images, FLAIR and Diffusion Weighted Images (DWI), but not T1-

weighted images. Contrast-enhancement is not a feature. To date, the changes have been most consistently seen on proton density and FLAIR images.

High signal in the pulvinar has been described in one single case report of benign intracranial hypertension, cat-scratch disease, Alpers' syndrome and post-infectious encephalitis, but the clinical and/or radiological features of these cases are clearly distinguishable from vCJD.

The 'pulvinar sign' is consistent with a diagnosis of *Probable* vCJD in the appropriate clinical context and can reliably distinguish vCJD from sCJD. Although other conditions may cause thalamic and other grey matter hyperintensity, in vCJD the highest signal is always in the pulvinar of the thalamus, and this is an important distinguishing feature.

Characteristic hyperintensity changes are seen in other grey matter structures in vCJD. High signal changes are seen in the dorsomedial nuclei of the thalamus in 56% of cases, and also less often in the periaqueductal grey matter and in the white matter.

Additionally, cerebral atrophy is seen in only a minority of patients with vCJD even with advanced disease, in contrast to the diffuse atrophy seen in sCJD.

One of the most important clinical differential diagnoses of vCJD is sCJD. In sCJD high signal is seen in the putamen and caudate nuclei in two-thirds of cases. High signal sometimes may be seen also in the thalamus in sCJD, but the signal intensity of the pulvinar is always less than the signal intensity of the putamen in sCJD.

The consultation recommended that when undertaking brain imaging for suspect cases of vCJD, the study should include T2-weighted, proton density-weighted, FLAIR and, where available, DWI sequences in the axial (anterior commissure-posterior commissure) plane to demonstrate the changes to best advantage.

Although the pulvinar sign is commonly present in vCJD, it is often overlooked during primary reporting, and has also been over-reported by clinicians with limited experience of the MRI changes of vCJD. Therefore it is recommended that MRI scans of suspected cases should be reviewed at a recognized reference centre (see Annex VII). Digital archiving of all images is recommended also to allow retrospective analysis in difficult cases.

The role of tonsil biopsy and lymphoreticular tissues in the diagnosis of vCJD

Although the precise role of lymphoreticular tissues in the pathogenesis of TSEs remains unclear, the pre-clinical involvement of various lymphoid organs has long been recognized. The diagnostic implications of this feature have been investigated in vCJD, sporadic, familial and iatrogenic CJD.

Tonsillar Biopsy

Positive results were first demonstrated in tonsil tissue taken at necropsy from a neuropathologically confirmed vCJD patient. A subsequent analysis of various lymphoid tissues, including palatine tonsil obtained at necropsy did not test positive for PrP^{Sc} in a

small number of patients with sCJD or Gerstmann-Sträussler-Scheinker disease. In a study using post-mortem tonsillar tissue, all nine of the vCJD cases tested showed the presence of PrP^{Sc}, but none of 16 sporadic sCJD cases nor the single iatrogenic CJD case. Table 5 shows the results of ante-mortem tonsil biopsies.

	Positive Tonsil Biopsy	Negative Tonsil Biopsy
Definite vCJD	3	0
Probable vCJD*	3	0
Possible* or suspected vCJD	3	0
2 familial CJD 2 sporadic CJD	0	4
Clinically unlikely CJD	0	7

*As defined by Will et al. Ann Neurol 2000; 47:575-582.

Table 5. Ante-mortem tonsil biopsy results

The reason tonsillar tissue contains PrP^{Sc} positivity in vCJD but not in other forms of CJD is unknown, but presumably reflects either a property of the agent strain in humans or the peripheral route of infection.

The above results suggested that ante-mortem tonsil biopsy could be used as a diagnostic test in patients suspected to have vCJD and a positive result has now been incorporated into the criteria produced by the UK authorities for a *Probable* case of vCJD. However, the use of this procedure in patients suspected to have vCJD is controversial and concern has been expressed regarding its potential morbidity (e.g. bleeding, infection and the risk of general anaesthesia). Unlike MRI, tonsil biopsy cannot provide specific information on any of the differential diagnostic possibilities for vCJD. Data to exclude the possibility of a false negative or false positive tonsil biopsy should be sought in future publications. Expertise is required in the accurate assessment of lymphoreticular tissues to diagnose vCJD and it is suggested that such samples should be sent to one of the reference centres listed in Appendix VII for review. On the basis of the published data, tonsil biopsy cannot be recommended as a routine diagnostic procedure in the investigation of vCJD, and it is not recommended as a screening procedure, not least because most suspect cases will not have vCJD. For suspect cases without bilateral pulvinar high signal on MRI, tonsil biopsy has a role in the classification of *Probable* but not *Definite* vCJD.

Lymphoreticular tissues

Other lymphoreticular tissues of vCJD patients contain PrP^{Sc}, with deposition in the germinal centres and apparently involving follicular dendritic cells and macrophages. Germinal centre involvement occurs in all lymphoid tissues, but is most evident in the tonsil and spleen. All adequate samples of tonsil, spleen and lymph node taken from confirmed

vCJD cases have tested positive for PrP^{Sc} whereas negative results have been obtained in those sCJD and iatrogenic cases studied.

Consequently immunocytochemistry of lymphoreticular tissue samples can be used to diagnose *Probable* vCJD. Various lymphoreticular tissues can be utilized, but tonsils are by far the best candidate due to the large number of germinal centres. If tonsils are not available, the next best candidate is spleen tissue; if spleen is unavailable, then peripheral lymph nodes can be sampled in which case, multiple sampling is necessary in order to increase the chances of detecting PrP. In this situation an extremely careful examination is required, since the germinal centres of lymph nodes are small. Some additional frozen material should always be saved for Western blot examination; a Western blot negative for PrP will be useful to confirm a negative immunohistochemistry finding, and can also rule out a false positive due to incomplete digestion of PrP^C. In countries where post-mortem examination is not accepted or cannot be performed, post-mortem needle biopsy of the spleen, which is not disfiguring, is suggested.

It is to be emphasized that a lymphoid tissue positive for PrP together with the characteristic clinical symptoms and signs can only support a diagnosis of *Probable* vCJD. The finding of negative lymphatic tissues cannot exclude the diagnosis of vCJD, but if multiple large samples are all negative, then the likelihood of vCJD is reduced. As stated earlier, lymphoreticular samples should be sent for confirmation to the reference centres listed in Annex VII.

III. Definite vCJD

The role of neuropathology in the diagnosis of vCJD

All forms of CJD display the characteristic neuropathological findings of spongiform lesions, reactive astrocytosis and neuronal loss. The pathological form of the prion protein (PrP^{Sc}) accumulates in infected brains and in some cases (kuru, Gerstmann-Sträussler-Scheinker, 10% of familial CJD and always in vCJD) forms 'amyloid' plaques that are birefringent when stained with Congo red.

The neuropathology of vCJD is significantly different from sCJD. In particular, a large number of PrP amyloid plaques surrounded by a halo of spongiform change ('florid plaques') are seen, particularly in the cerebral and cerebellar cortical grey matter. The 'florid plaques' are not specific for vCJD but their widespread distribution is characteristic of the disease.

In addition to amyloid plaques, vCJD displays some other neuropathological features that make it distinguishable from other human prion diseases. For a detailed description see Annex V.

The extent and intensity of pathological features increase as the disease progresses and therefore, the pathological characteristics become clearly evident in patients with a disease of long duration. Posterior thalamic astrocytosis is more extensive in vCJD than in other forms of the disease (i.e. the total number of astrocytes is higher in vCJD than in sCJD or Fatal Familial Insomnia). This severe astrocytosis is accompanied by marked neuronal loss in vCJD, and the anatomical distribution of these changes correlates with the abnormal hyperintensity on MRI.

Other neural tissues, including the trigeminal ganglia, dorsal root ganglia and retina are also positive for PrP^{Sc}.

According to the case definition for vCJD, neuropathological examination remains essential for the diagnosis of *Definite* vCJD. (Neuropathological criteria are described in Annex V).

Considering the extremely serious implications of a diagnosis of vCJD in countries not known to have the disease, neuropathology is recommended in such situations. A *Definite* diagnosis of vCJD requires neuropathological confirmation, and furthermore, it was recommended that sample materials (frozen and fixed brain) are sent to one of the reference centres listed in Annex VII. This will reduce the risk of a false diagnosis³ due to possible technical difficulties from performing the test infrequently.

Suggested approaches to post-mortem examination

In countries where post-mortem examination is not accepted or cannot be performed, post-mortem biopsy can be used as an alternative, but in this case multiple sampling (4 to 5 large pieces) from different brain regions is required in order to perform an adequate histopathological evaluation. Nevertheless, in cases where only brain biopsy is available, a negative result does not exclude the diagnosis of vCJD.

It is emphasized that the only rationale for a brain biopsy in life remains the diagnosis of another treatable disease; brain biopsy in a living person is not recommended for the diagnosis of vCJD or sCJD. A hierarchy for histopathologic diagnosis of vCJD is provided in Table 6.

1. Full autopsy with fixed and frozen tissue (for Western blot examination) retained from Central Nervous System (CNS), lymphoid and other tissues
2. Limited autopsy with fixed and frozen tissue retained from CNS tissues
3. Limited autopsy with fixed CNS tissue only
4. Brain biopsy with fixed and frozen tissue retained
5. Brain biopsy with fixed tissue only
6. Lymphoreticular tissue 'biopsy' post-mortem with fixed and frozen tissue retained
7. Lymphoreticular tissue 'biopsy' post-mortem with fixed tissue only

Table 6. Hierarchy for tissue diagnosis of vCJD

Western blot analysis of PrP isotype in the diagnosis of vCJD

Distinct strains of naturally occurring sheep scrapie have been isolated in mice. To explain how a single polypeptide chain (PrP^{Sc}) can encode multiple disease phenotypes, it is necessary to assume that the protein itself can adopt different pathological conformations.

³ False negative results related to problems in PrP^{Sc} detection are possible, as well as false positive results related to PrP^C detection.

Recently, several human PrP^{Sc} types associated with different clinical phenotypes of CJD have been identified. The fragment size after limited proteolysis, and the ratio of the three PrP glycoforms (diglycosylated, monoglycosylated and unglycosylated PrP) visible after electrophoresis on polyacrilamide gel, is maintained after passage in transgenic mice expressing human PrP. According to these data, possible molecular classifications of CJD have been published, but the results are still preliminary and some discrepancies between different laboratories have been reported.

In extracts taken from the brain tissue of persons with vCJD, the ratio of glycosylated to non-glycosylated PrP differs from sCJD and is similar to experimentally transmitted BSE. Although the use of PrP strain typing in the differential diagnosis of sCJD and vCJD is promising, it was not recommended by this consultation as a routine marker in clinical settings.

Handling of instruments used to diagnose vCJD

See WHO Infection Control Guidelines for Transmissible Spongiform Encephalopathies, Report of a WHO Consultation, Geneva, Switzerland, 23-26 March 1999, WHO/CDS/CSR/APH/2000.3 available at:
<http://www.who.int/emc-documents/tse/docs/whocdscsr2003.pdf>

In the past, sporadic CJD has been transmitted from person-to-person by different medical procedures including grafts/transplants of dura mater, treatment with human-derived pituitary hormone and contaminated neurosurgical instruments. This, together with the knowledge that PrP^{Sc} has been demonstrated in lymphoid tissues (spleen, tonsils, gut-associated lymphoid tissue including appendix, and lymph nodes) of patients with established vCJD, raise the possibility of transmission of the disease through cross-contamination by lymphoid tissues of pre-symptomatic patients. Therefore, in addition to the above guidelines, instruments used for lymphoid tissue biopsies in suspected vCJD cases must be handled as per the recommendations for the brain tissue in the WHO Infection Control Guideline. For economic reasons the instruments can be quarantined until the final results are available. If the diagnosis of a TSE is excluded, the instruments may be sterilized as per routine procedures and returned to circulation.

Annex I – Case definition for vCJD

- | | | |
|-----|---|--|
| I | A | Progressive neuropsychiatric disorder |
| | B | Duration of illness > 6 months |
| | C | Routine investigations do not suggest an alternative diagnosis |
| | D | No history of potential iatrogenic exposure |
| | E | No evidence of a familial form of TSE |
| II | A | Early psychiatric symptoms ¹ |
| | B | Persistent painful sensory symptoms ² |
| | C | Ataxia |
| | D | Myoclonus or chorea or dystonia |
| | E | Dementia |
| III | A | EEG does not show the typical appearance of sporadic CJD ³
(or no EEG performed) |
| | B | MRI brain scan shows bilateral symmetrical pulvinar high signal ⁴ |
| IV | A | Positive tonsil biopsy ⁵ |

DEFINITE: I A **and** neuropathological confirmation of vCJD ⁶

PROBABLE: I **and** 4/5 of II **and** III A **and** III B

OR

I **and** IV A

POSSIBLE: I and 4/5 of II and III A

¹ depression, anxiety, apathy, withdrawal, delusions; see Annex VIII.

² this includes both frank pain and/or dysaesthesia.


³ generalized triphasic periodic complexes at approximately one per second; see Annex VI.

⁴ relative to the signal intensity of other deep grey matter nuclei and cortical grey matter.

⁵ tonsil biopsy is not recommended routinely, nor in cases with EEG appearances typical of sporadic CJD, but may be useful in suspect cases in which the clinical features are compatible with vCJD and where MRI does not show bilateral pulvinar high signal.

⁶ spongiform change and extensive PrP deposition with florid plaques, throughout the cerebrum and cerebellum, see Annex V.

Annex II – Agenda for the consultation

 Time	Subject	Presenter
08.30	Introduction and selection of chair	
08.45	Revision of the case definition for vCJD - experience in the United Kingdom	Professor Robert Will
09.15	Questions	
09.30	Neuropathology of vCJD	Professor James Ironside
09.50	Questions	
10.00	Use of the EEG to diagnose vCJD	Dr Richard Knight
10:20	Questions	
10.30-11.00	Coffee	
11.00	14-3-3 to diagnose vCJD	Dr Alison Green
11.20	Questions	
11.30	Scans (MRI) to diagnose vCJD	Dr Don Collie
11.50	Questions	
12.00	Tonsil biopsy to diagnose vCJD	Dr Martin Zeidler
12.20	Questions	
12.30-13.30	Lunch	
13.30	Working Group discussion of problems in diagnosis of vCJD in developing countries	All
14.00	Development of case definition	All
14:30-15:00	Coffee	
17.00	Meeting adjourns	

Annex III – List of scientific presentations to the consultation

Professor Robert Will
Revision of the case definition for vCJD - experience in the United Kingdom

Professor James Ironside
Neuropathology of vCJD

Dr Richard Knight
Use of the EEG to diagnose vCJD

Dr Alison Green
14-3-3 to diagnose vCJD

Dr Don Collie
Scans (MRI) to diagnose vCJD

Dr Martin Zeidler
Tonsil biopsy to diagnose vCJD

Annex IV - Participants

WHO Regional Office for the Americas (AMRO)

Dr Paul Brown, Laboratory of Central Nervous System Studies, National Institute of Neurological Disorders and Stroke, National Institutes of Health, Bldg. 36, Room 4 A05, 36 Convent Drive, Bethesda, MD 20892-4122, USA.

WHO Regional Office for Europe (EURO)

Dr Donald Collie, Consultant, Neuroradiologist, Department of Neuroradiology, D.C.N., Western General Hospital, Crewe Road South Edinburgh, EH4 2XU, United Kingdom.

Dr Alison JE Green, National CJD Surveillance Unit, Western General Hospital, Crewe Road South Edinburgh, EH4 2XU, United Kingdom United Kingdom.

Professor James Ironside, National CJD Surveillance Unit, Western General Hospital, Crewe Road South Edinburgh, EH4 2XU, United Kingdom.

Dr Christa Jarius, Institute of Neurology, University of Vienna, 48 Waehringuer Guertel 18-20, 1097 Vienna, Austria.

Dr Richard Knight, National CJD Surveillance Unit, Western General Hospital, Crewe Road South Edinburgh, EH4 2XU, United Kingdom United Kingdom

Professor Dr Jerzy Kulczycki, Consultant, Institute of Psychiatry and Neurology, 1st Neurological Department, Sobieskiego 1/9, 02-957 Warsaw, Poland.

Dr Catherine Majtényi, Chief, Department of Neuropathology, National Institute of Psychiatry and Neurology, 27/1 Huvosvolgyi 116. 1281 Budapest, Hungary.

Dr Eva Mitrova, Chief, National Reference Center of Slow Virus, Neuro-Infections, Department of SVN, Institute of Preventive and Clinical Medicine, Limbova 14, 83301 Bratislava, Republic of Slovakia.

Dr Maurizio Pocchiari, Registry of Creutzfeldt-Jakob Disease, Laboratory of Virology, Istituto Superiore di Sanita, Viale Regina Elena 299, 00161, Rome, Italy.

Dr Hester Ward (**Rapporteur**), Consultant Epidemiologist, National CJD Surveillance Unit, Western General Hospital, Crewe Road South Edinburgh, EH4 2XU, United Kingdom, United Kingdom.

Professor Robert Will (**Chairman**), National CJD Surveillance Unit, Western General Hospital, Crewe Road South Edinburgh, EH4 2XU, United Kingdom.

Dr Martin Zeidler (**Rapporteur**), Ward 31, Department of Clinical Neuroscience, Western General Hospital, Crewe Road, Edinburgh, EH4 2XU, United Kingdom.

Dr Inga Zerr, Department of Neurology, Faculty of Medicine
Georg-August-University, Robert-Koch Str. 40, D-37075, Göttingen, Germany.

WHO Regional Office for the Western Pacific (WPRO)

Professor Dong Xiaoping, Chinese Academy of Preventive Medicine, Ying Xin Jie,
Xuan Xu Qu, 100052 Beijing, China.

WHO Secretariat

Dr Paola Pergami, Medical Officer, Animal and Food-related Public Health Risks,
Department of Communicable Disease Surveillance and Response, World Health
Organization, Geneva, Switzerland.

Dr Maura Ricketts, Medical Officer, Animal and Food-related Public Health Risks,
Department of Communicable Disease Surveillance and Response, World Health
Organization, Geneva, Switzerland.

Annex V - Pathological characteristics of vCJD

The pathological aspects typical of TSE (spongiosis, neuronal loss, reactive astrocytosis and the accumulation in the affected brain of PrP^{Sc}) are present in vCJD as well.

However, the following key features are characteristic of vCJD:

1. Abundant kuru-type fibrillary PrP plaques, often surrounded by a halo of spongiform change (the “florid” plaque).
2. Multiple small PrP plaques occurring in cluster within the cerebral and cerebellar cortex, not related to spongiform changes.
3. Amorphous PrP deposits around neurons and blood vessels in the cerebral and cerebellar cortex.

Immunocytochemistry for PrP is an invaluable aid to diagnosis, although the large fibrillary plaques are easily visualized by haematoxylin/eosin stain. Plaques can also be identified by periodic acid/Schiff or Gallyas silver stains, but the amorphous PrP deposits are best visualized by immunocytochemistry.

Additional neuropathologic characteristics are:

1. Spongiform change most prominent in the basal ganglia, with dense perineuronal and periaxonal PrP deposition.
2. Severe thalamic astrocytosis and neuronal loss, particularly involving the dorsomedial and posterior nuclei (including the pulvinar).
3. Massive accumulation of PrP, often with focal distribution, in the cerebellar cortex including the molecular and granular layer with occasional plaques in the white matter.
4. Punctate neuronal staining for PrP in the pontine nuclei.

Annex VI - EEG criteria for sporadic CJD

- Pseudo periodic activity
 - Variability of intercomplex intervals is <500ms
 - Continuous periodic activity for at least one 10 second period.
- Bi- or tri- phasic morphology of periodic complexes.
- Duration of majority of complexes ranges from 100 to 600 ms.
- Periodic complexes can be generalized or lateralized, but not regional or asynchronous.

Annex VII – List of reference centres

The following centres have kindly agreed to perform tests on suspected vCJD cases if required. Please contact the named person for more information before sending samples.

For clinical evaluation or any diagnostic test

Professor Robert G. Will, National CJD Disease Surveillance Unit, Western General Hospital, Crewe Road, Edinburgh, EH4 2XU, United Kingdom.

Dr Richard Knight, National CJD Surveillance Unit, Western General Hospital, Crewe Road, Edinburgh, EH4 2XU, United Kingdom.

Professor John Collinge, MRC Prion Unit, The National Hospital for Neurology and Neurosurgery, Queen Square, GB-London WC1N 3BG, United Kingdom.

Professor Colin Masters, Department of Pathology, University of Melbourne, Parkville, Victoria 3010, Australia.

For MRI evaluation

Dr Donald Collie, Department of Neuroradiology, D.C.N., Western General Hospital, Crewe Road, South Edinburgh EH4 2XU, United Kingdom

For pathology and Western blot

Professor James Ironside, National CJD Surveillance Unit, University of Edinburgh, Western General Hospital, Crewe Road, Edinburgh EH4 2XU, United Kingdom.

Professor Herbert Budka, Institute of Neurology, University of Vienna, AKH 4J, POB 48, A-1097 Vienna, Austria

Professor Nicolas Kopp, Neuropathologie, Hopital Neurologique, 59 Boul Pinel, 69003 Lyon, France.

Professor Pierluigi Gambetti, Institute of Pathology, Case Western Reserve University School of Medicine, 10900 Euclid Ave., Cleveland, OH 44106, USA.

For 14-3-3 detection

Dr Alison JE Green, National CJD Surveillance Unit, Western General Hospital, Crewe Road, Edinburgh EH4 2XU, United Kingdom.

Dr Inga Zerr, Prionforschungsgruppe, Neurologische Klinik und Poliklinik, POB 37 42, Rotert-Koch-Strs.40, 370 75 Gottingen, Germany.

Annex VIII - Clinical features during illness and at onset, of variant CJD, sporadic CJD and suspect vCJD cases with an alternative final diagnosis (non-cases)

Feature	vCJD	SCJD	Non-cases*
Psychiatric symptoms	98 (69)	55 (40)	90
Sensory disturbance	70 (19)	10 (5)	20
Ataxia	100 (9)	85 (40)	65
Forgetfulness	85 (17)	>95 (50)	-
Involuntary movements	100 (5)	90 (15)	-
Myoclonus	70 (0)	80 (<2)	65
Chorea	55 (0)	10 (1)	25 [†]
Dystonia	30 (4)	15 (0)	20
Upgaze paresis	36 (0)	5	7
Dementia	100 (0)	>95	80
Akinetic mutism	51 (0)	55	30

Values are percentage of patients with the feature during the illness course and at onset in parenthesis.

*Suspect vCJD cases with an alternative final diagnosis (n=27)

[†]Includes patients described as fidgety.

Annex IX – Selected references

CJD and vCJD risk and epidemiology

1. Andrews NJ, Farrington CP, Cousens SN, Smith PG, Ward H, Knight RSG, Ironside JW, Will RG. Incidence of variant Creutzfeldt-Jakob disease in the UK. *Lancet* 2000 356: 481-482
2. Cooper JD, Bird SM, de Angelis D. Prevalence of detectable abnormal prion protein in persons incubating vCJD: plausible incubation periods and cautious inference. *J Epidemiol Biostat* 2000 5(4): 209-219
3. Cousens SN, Linsell L, Smith PG, Chandrakumar M, Wilesmith JW, Knight RSG, Zeidler M, Stewart G, Will RG. Geographical distribution of variant CJD in the UK (excluding Northern Ireland). *Lancet* 1999 353: 18-21
4. Ghani AC, Donnelly CA, Ferguson NM, Anderson RM. Assessment of the prevalence of vCJD through testing tonsils and appendices for abnormal prion protein. *Proc R Soc Lond B Biol Sci* 2000 267 (1438): 23-29
5. Ghani AC, Ferguson NM, Donnelly CA, Anderson RM. Predicted vCJD mortality in Great Britain. *Nature* 2000 406 (6796): 583-584
6. Holan RC, Khan AS, Belay ED, Schonberger LB. Creutzfeldt-Jakob disease in the US, 1979-1994: using national mortality data to assess the possible occurrence of variant cases. *Emerging Infectious Diseases* 1996 2 (4): 333-337
7. van Duijn CM, Delasnerie-Laupretre N, Masullo C, Zerr I, de Silva R, Wientjens DPWM, Brandel J-P, Weber T, Bonavita V, Zeidler M, Alperovitch A, Poser S, Granieri E, Hofman A, Will RG. Case-control study of risk factors of Creutzfeldt-Jakob disease in Europe during 1993-95. *Lancet* 1998 351: 1081-1085
8. Ward HJT. Surveillance of variant Creutzfeldt-Jakob disease in the UK. *Eurosurveillance* 2000 5 (9): 90-94
9. Will RG, Alperovitch A, Poser S, Pocchiari M, Hofman A, Mitrova E, de Silva R, D'Alessandro M, Delasnerie-Laupretre N, Zerr I, van Duijn C. Descriptive epidemiology of Creutzfeldt-Jakob disease in six European countries, 1993-1995. *Ann Neurol* 1998 43: 763-767

Transmission studies

10. Bruce ME, Will RG, Ironside JW, McConnell I, Drummond D, Suttie A, McCardle L, Chree A, Hope J, Birkett C, Cousens S, Fraser H, Bostock CJ. Transmissions to mice indicate that 'new variant' CJD is caused by the BSE agent. *Nature* 1997 6650: 498-501
11. Lasmezas CI, Fournier JG, Nouvel V, Boe H, Marce D, Lamoury F, Kopp N, Hauw JJ, Ironside J, Bruce M, Dormont D, Deslys JP. Adaptation of the bovine spongiform encephalopathy agent to primates and comparison with Creutzfeldt-Jakob disease: implications for human health. *Proc Natl Acad Sci U S A* 2001 98(7): 4142-4127
12. Scott MR, Will RG, Ironside J, Nguyen H-OB, Tremblay P, DeArmond SJ, Prusiner SB. Compelling transgenetic evidence for transmission of bovine spongiform encephalopathy prions to humans. *PNAS* 1999 96 (26): 15137-15142
13. Will RG, Ironside JW. Commentary: Oral infection by the bovine spongiform encephalopathy prion. *Proc Natl Acad Sci* 1999 96: 4738-4739

Surveillance

14. Majeed A, Lehmann P, Kirby L, Knight R, Coleman M. Extent of misclassification of death from Creutzfeldt-Jakob disease in England 1979-96: retrospective examination of clinical records. *BMJ* 2000 320:145-147
15. Verity CM, Nicoll A, Will RG, Devereux G, Stellitano L. Variant Creutzfeldt-Jakob disease in UK children: a national surveillance study. *Lancet* 2000 356: 1224-1227
16. Zerr I, Brandel J-P, Masullo C, Wientjens D, De Silva R, Zeidler M, Granieri E, Sampaolo S, van Duijn C, Delasnerie-Laupretre N, Will R, Poser S. European surveillance on Creutzfeldt-Jakob disease: a case-control study for medical risk factors. *J Clin Epid* 2000 53: 747-754

Clinical aspects of vCJD

17. Bowen J, Mitchell T, Pearce R, Quinn N. Chorea in new variant Creutzfeldt-Jacob disease. *Mov Disord* 2000 15 (6): 1284-1285
18. Collinge J. Variant Creutzfeldt-Jakob disease. *Lancet* 1999 354 (9175): 317-323
19. Greene JD, Hodges JR, Ironside JW, Warlow CP. Progressive aphasia with rapidly progressive dementia in a 49 year old woman. *JNNP* 1999 66: 238-243
20. Lorains JW, Henry C, Agbamu DA, Rossi M, Bishop M, Will RG, Ironside JW. Variant Creutzfeldt-Jakob disease in an elderly patient. *Lancet* 2001 357 (9265): 1339-1340
Kapur N, Ironside J, Abbott P, Warner G, Turner A. A neuropsychological-neuropathological case study of variant Creutzfeldt-Jakob disease. *Neurocase* 2001 7 (3): 261-267
21. Macleod MA, Knight R, Stewart G, Zeidler M, Will R. Clinical features of nvCJD. *European Journal of Neurology* 1999 6 (3): 26-27
22. Macleod MA, Knight R, Stewart G, Zeidler M, Will R. Sensory features of variant Creutzfeldt-Jakob disease. *JNNP* 2000 69: 413-414
23. Will RG, Stewart G, Zeidler M, Macleod MA, Knight RSG. Psychiatric features of new variant Creutzfeldt-Jakob disease. *Psychiatric Bulletin* 1999 23: 264-267
24. Will RG, Zeidler M, Stewart GE, Macleod MA, Ironside JW, Cousens SN, Mackenzie J, Estibeiro K, Green AJE, Knight RSG. Diagnosis of new variant Creutzfeldt-Jakob disease. *Ann Neurol* 2000 47: 575-582
25. Will RG, Ironside JW, Zeidler M, Cousens SN, Estibeiro K, Alperovitch A, Poser S, Pocchiari M, Hofman A, Smith PG. A new variant of Creutzfeldt-Jakob disease in the UK. *Lancet* 1996 347(9006): 921-925
26. Will RG, Zeidler M, Stewart GE, Macleod MA, Ironside JW, Cousens SN, Mackenzie J, Estibeiro K, Green AJ, Knight RS. Diagnosis of new variant Creutzfeldt-Jakob disease. *Ann Neurol* 2000 47(5): 575-582
27. Zeidler M, Johnstone EC, Bamber RW, Dickens CM, Fisher CJ, Francis AF, Goldbeck R, Higgo R, Johnson-Sabine EC, Lodge GJ, McGarry P, Mitchell S, Tarlo L, Turner M, Ryley P, Will RG. New variant Creutzfeldt-Jakob disease: psychiatric features. *Lancet* 1997 350(9082): 908-910
28. Zeidler M, Stewart GE, Barraclough CR, Bateman DE, Bates D, Burn DJ, Colchester AC, Durward W, Fletcher NA, Hawkins SA, Mackenzie JM, Will RG. New variant Creutzfeldt-Jakob disease: neurological features and diagnostic tests. *Lancet* 1997 350 (9082): 903-907.
29. Zeidler M, Ironside JW. The new variant of Creutzfeldt-Jakob disease. *Rev Sci Tech* 2000 1: 98-120

CSF findings in CJD

30. Green AJE, Thompson EJ, Stewart G, Zeidler M, Mackenzie J, Macleod MA, Will RG, Knight RSG. The use of CSF 14-3-3 and other brain specific proteins in the diagnosis of variant CJD. *Journal Neurol Neurosurg Psychiatry* 2001 70: 744-748
31. Knight R. Creutzfeldt-Jakob disease: clinical features, epidemiology and tests. *Electrophoresis* 1998 19: 1306-1310
32. Kretzschmar H, Ironside J, DeArmond S. Diagnostic criteria for sporadic Creutzfeldt-Jakob disease. *Arch Neurol* 1996 53: 913-920
33. Zerr I, Bodemer M, Racker S et al. Cerebrospinal fluid concentration of neuron-specific enolase in diagnosis of Creutzfeldt-Jakob disease. *Lancet* 1995 345: 1609-1610
34. Collinge J. New diagnostic tests for prion diseases. *N Engl J Med*. 1996 335 (13): 963-965
35. Zerr I, Pocchiari M, Collins S, Brandel J-P, de Pedro Cuesta J, Knight RS, Bernheimer H, Cardone F, Delasnerie-Laupretre N, Cuadrado Corrales N, Ladogana A, Bodemer M, Fletcher A, Awan T, Ruiz Bremon A, Budka H, Laplanche J-L, Will RG, Poser S. Analysis of EEG and CSF 14-3-3 proteins as aids to the diagnosis of Creutzfeldt-Jakob disease. *Neurology* 2000 55(6): 811-815
36. Green AJE, Thompson EJ, Zeidler M, Stewart G, Mackenzie J, Macleod MA, Knight RSG, Will RG. Raised concentrations of brain specific proteins in patients with sporadic and variant CJD. *JNNP* 2000 69: 419
37. Collins S, Boyd A, Fletcher A, Gonzales M, McLean CA, Byron K, Masters CL. Creutzfeldt-Jakob disease: diagnostic utility of 14-3-3 protein immunodetection in cerebrospinal fluid. *J Clin Neurosci* 2000 7(3): 203-208
38. Collins S, Boyd A, Fletcher A, Gonzales MF, McLean CA, Masters CL. Recent advances in the pre-mortem diagnosis of Creutzfeldt-Jakob disease. *J Clin Neurosci* 2000 7 (3): 195-202
39. Beaudry P, Cohen P, Brandel JP, Delasnerie-Laupretre N, Richard S, Launay JM, Laplanche JL. 14-3-3 protein, neuron-specific enolase, and S-100 protein in cerebrospinal fluid of patients with Creutzfeldt-Jakob disease. *Dement Geriatr Cogn Disord* 1999 10 (1): 40-46
40. Otto M, Wiltfang J, Tumani H, Zerr I, Lantsch M, Kornhuber J, Weber T, Kretzschmar HA, Poser S. Elevated levels of tau-protein in cerebrospinal fluid of patients with Creutzfeldt-Jakob disease. *Neurosci Lett* 1997 225 (3): 210-212
41. Lemstra AW, van Meegen MT, Vreyling JP et al. 14-3-3 testing in diagnosing Creutzfeldt-Jakob disease. A prospective study in 112 patients. *Neurology* 2000 55: 514-516
42. Hsich G, Kenney K, Gibbs CJ, Lee KH, Harrington MG. The 14-3-3 brain protein in cerebrospinal fluid as a marker for transmissible spongiform encephalopathies. *N Engl J Med* 1996 335: 924-930
43. Zerr I, Bodemer M, Gefeller O et al. Detection of 14-3-3 protein in the cerebrospinal fluid supports the diagnosis of Creutzfeldt-Jakob disease. *Ann Neurol* 1998 43: 32-37
44. Zeidler M. 14-3-3 cerebrospinal fluid protein and Creutzfeldt-Jakob disease. *Ann Neurol* 2000 47: 683

MRI in the diagnosis of sCJD and vCJD

45. Collie DA, Sellar RJ, Zeidler M, Colchester AC, Knight R, Will RG MRI of Creutzfeldt Jakob disease: imaging features and recommended MRI protocol. *Clin Radiol* 2001 56 (9): 726-39
46. De Priester JA, Jansen GH, de Kruijk JR, Wilmink JT. New MRI findings in Creutzfeldt-Jakob disease: high signal in the globus pallidus on T1-weighted images. *Neuroradiology* 1999 41 (4): 265-268
47. Gertz H-J, Henkes H, Cervos-Navarro J. Creutzfeldt-Jakob disease: Correlation of MRI and neuropathological findings. *Neurology* 1988 38 1481-1482
48. Nitrini R, Mendonca RA, Huang N, LeBlanc A, Livramento JA, Marie SK. Diffusion-weighted MRI in two cases of familial Creutzfeldt--Jakob disease. *J Neurol Sci* 2001 184 (2): 163-167.
49. Saito T, Isozumi K, Komatsumoto S, Nara M, Suzuki K, Dohura K. [A case of codon 232 mutation-induced Creutzfeldt-Jakob disease visualized by the MRI-FLAIR images with atypical clinical symptoms]. *Rinsho Shinkeigaku* 2000 40 (1): 51-54
50. Schroter A, Zerr I, Henkel K, Tschampa HJ, Finkenstaedt M, Poser S. Magnetic resonance imaging in the clinical diagnosis of Creutzfeldt-Jakob disease. *Arch Neurol* 2000 57 (12): 1751-1757
51. Zeidler M, Collie DA, Macleod MA, Sellar RJ, Knight R. FLAIR MRI in sporadic Creutzfeldt-Jakob disease. *Neurology* 2001 56 (2): 282
52. Zeidler M, Sellar RJ, Collie DA, Knight R, Stewart G, Macleod MA, Ironside JW, Cousens S, Colchester AFC, Hadley DM, Will RG. The pulvinar sign on magnetic resonance imaging in variant Creutzfeldt-Jakob disease. *Lancet* 2000 355: 1412-1418
53. Zeidler M, Will RG, Ironside JW, Sellar R, Wardlaw J. Creutzfeldt-Jakob disease and bovine spongiform encephalopathy. Magnetic resonance imaging is not a sensitive test for Creutzfeldt-Jakob disease. *BMJ* 1998 312: 844

Tonsil biopsy and lymphoreticular tissue in the diagnosis of vCJD

54. Bruce ME, McConnell I, Will RG, Ironside JW. Detection of variant Creutzfeldt-Jakob disease infectivity in extraneural tissues. *Lancet* 2001 358 (9277): 208-209
55. Hill AF, Butterworth RJ, Joiner S, Jackson G, Rossor MN, Thomas DJ, Frosh A, Tolley N, Bell JE, Spencer M, King A, Al-Sarraj S, Ironside JW, Lantos PL, Collinge J. Investigation of variant Creutzfeldt-Jakob disease and other human prion diseases with tonsil biopsy samples. *Lancet* 1999 353: 183-189
56. Hill AF, Zeidler M, Ironside J, Collinge J. Diagnosis of new variant Creutzfeldt-Jakob disease by tonsil biopsy. *Lancet* 1997 349: 99-100
57. Hilton DA, Fathers E, Edwards P, Ironside JW, Zajicek J. Prion immunoreactivity in appendix before clinical onset of variant Creutzfeldt-Jakob disease. *Lancet* 1998 352: 703-704
58. Jeffrey M, McGovern G, Martin S, Goodsir CM, Brown KL. Cellular and sub-cellular localisation of PrP in the lymphoreticular system of mice and sheep. *Arch Virol Suppl* 2000 16: 23-38
59. Jeffrey M, Martin S, Thomson JR, Dingwall WS, Begara-McGorum I, Gonzalez L. Onset and distribution of tissue prp accumulation in scrapie-affected suffolk sheep as demonstrated by sequential necropsies and tonsillar biopsies. *J Comp Pathol* 2001 125 (1): 48-57
60. Kawashima T, Furukawa H, Doh-ura K, Iwaki T. Diagnosis of new variant Creutzfeldt-Jakob disease by tonsil biopsy. *Lancet* 1997 350: 68-69

61. Schreuder BE, van Keulen LJ, Vromans ME, Langeveld JP, Smits MA. Tonsillar biopsy and PrPSc detection in the preclinical diagnosis of scrapie. *Vet Rec* 1998 142 (21): 564-568
62. Schreuder BEC, van Keulen LJM, Vromans MEW, Langeveld JPM, Smits MA. Preclinical test for prion disease. *Nature* 1996 381: 563
63. Wadsworth JD, Joiner S, Hill AF, Campbell TA, Desbruslais M, Luthert PJ, Collinge J. Creutzfeldt-Jakob disease using a highly sensitive immunoblotting assay. *Lancet* 2001 358 (9277): 171-180
64. Zeidler M, Knight R, Stewart G, Ironside JW, Will RG, Green AJE, Pocchiari M. Diagnosis of Creutzfeldt-Jakob disease. Routine tonsil biopsy for diagnosis of new variant Creutzfeldt-Jakob disease is not justified. *BMJ* 1999 318: 538-538

Neuropathological findings in sCJD and vCJD

65. Ironside JW, Head MW, Bell JE, McCardle L, Will RG. Laboratory diagnosis of variant Creutzfeldt-Jakob disease. *Histopathology* 2000 37 (1): 1-9
66. Ironside JW. Pathology of variant Creutzfeldt-Jakob disease. *Arch Virol Suppl* 2000 16: 143-151
67. Ironside JW. Neuropathological findings in new variant CJD and experimental transmission of BSE. *FEMS Immunology and Medical Microbiology* 1998 21: 91-95
68. McLean CA, Ironside JW, Alpers MP, Brown PW, Cervenakova L, Anderson RMcD, Masters CL. Comparative neuropathology of kuru with the new variant of Creutzfeldt-Jakob disease: evidence for strain of agent predominating over genotype host. *Brain Pathology* 1998 8: 429-437
69. Wadsworth JD, Joiner S, Hill AF, Campbell TA, Desbruslais M, Luthert PJ, Collinge J. Tissue distribution of protease resistant prion protein in variant Creutzfeldt-Jakob disease using a highly sensitive immunoblotting assay. *Lancet* 2001 358 (9277): 171-180

Genetic data

70. Alperovitch A, Zerr I, Pocchiari M, Mitrova E, de Pedro Cuesta J, Hegyi I, Collins S, Kretschmar H, van Duijn C, Will RG. Codon 129 prion protein genotype and sporadic Creutzfeldt-Jakob disease. *Lancet* 1999 353: 1673-1674
71. Head MW, Tissingh G, Uitdehaag BM, Barkhof F, Bunn TJ, Ironside JW, Kamphorst W, Scheltens P. Sporadic Creutzfeldt-Jakob disease in a young Dutch valine homozygote: atypical molecular phenotype. *Ann Neurol* 2001 50 (2): 258-261
72. Kovacs GG, Head MW, Bunn T, Laszlo L, Will RG, Ironside JW. Clinicopathological phenotype of codon 129 valine homozygote sporadic Creutzfeldt-Jakob disease. *Neuropathol Appl Neurobiol* 2000 26 (5):463-472
73. Windl O, Dempster M, Estibiero JP et al. Genetic basis of Creutzfeldt-Jakob disease in the United Kingdom: a systematic analysis of predisposing mutations and allelic variations in the PRNP gene. 1996 *Human Genetics* 98: 259-264

Prion strains

74. Collinge J, Sidle KC, Meads J, Ironside J, Hill AF. Molecular analysis of prion strain variation and the aetiology of 'new variant' CJD. *Nature* 1996 383 (6602): 685-690
75. Hill AF, Desbruslais M, Joiner S, Sidle KC, Gowland I, Collinge J, Doey LJ, Lantos P. The same prion strain causes vCJD and BSE. *Nature* 1997 389 (6650): 448-450

76. Parchi P, Castellani R, Capellari S, Ghetti B, Young K, Chen SG, Farlow M, Dickson DW, Sima AA, Trojanowski JQ, Petersen RB, Gambetti P. Molecular basis of phenotypic variability in sporadic Creutzfeldt-Jakob disease. *Ann Neurol* 1996 39 (6): 767-778
77. Parchi P, Giese A, Capellari S, Brown P, Schulz-Schaeffer W, Windl O, Zerr I, Budka H, Kopp N, Piccardo P, Poser S, Rojiani A, Streichemberger N, Julien J, Vital C, Ghetti B, Gambetti P, Kretschmar H. Classification of sporadic Creutzfeldt-Jakob disease based on molecular and phenotypic analysis of 300 subjects. *Ann Neurol* 1999 46 (2): 224-233
78. WHO working group on international reference materials for diagnosis and study of transmissible spongiform encephalopathies (TSEs).
<http://www.who.int/technology/biologicals.html>

Other theories

79. Churchill D, Churchill DJ, Will RG. Organophosphate exposure and variant Creutzfeldt-Jakob disease. *Lancet* 1999 353: 1410-1423

Relevant WHO documents

80. Report of a WHO Consultation on Public Health Issues related to Human and Animal Transmissible Spongiform Encephalopathies, with the participation of FAO and OIE, Geneva, Switzerland, 2-3 April 1996, WHO/EMC/DIS/96.147
81. Report of a WHO Consultation on Medicinal and other Products in Relation to Human and Animal Transmissible Spongiform Encephalopathies, with the participation of the Office International des Epizooties (OIE), Geneva, Switzerland, 24-26 March 1997, WHO/EMC/Z00/97.3, WHO/BLG/97.2
82. Global Surveillance, Diagnosis and Therapy of Human Transmissible Spongiform Encephalopathies: Report of a WHO Consultation, Geneva, Switzerland, 9-11 February 1998, WHO/EMC/ZDI/98.9
83. WHO Consultation on Public Health and Animal Transmissible Spongiform Encephalopathies: Epidemiology, Risk and Research Requirements with the participation of the Office International des Epizooties, Geneva, Switzerland, 1-3 December 1999, WHO/CDS/CSR/APH/2000.2
84. WHO Infection Control Guidelines for Transmissible Spongiform Encephalopathies, Report of a WHO Consultation, Geneva, Switzerland, 23-26 March 1999, WHO/CDS/CSR/APH/2000.3

Web sites

<http://www.who.int/emc/diseases/bse/index.html>
<http://www.who.it/HT/bse.htm>
<http://www.eurocjd.ed.ac.uk/>
<http://www.cjd.ed.ac.uk/>

This document provides the newly adopted definition for variant Creutzfeldt-Jacob disease (vCJD), the form of human prion disease linked to the epidemic of bovine spongiform encephalopathy (BSE) in cattle. The document is based upon the scientific presentations and discussions of a WHO consultation held in Edinburgh UK, on 17 May 2001.

In issuing this document, WHO aims to help public health departments and clinicians, particularly neurologists, in the surveillance and diagnosis of this new disease. The organization of the document reflects the clinical hierarchy used in the diagnosis of human diseases - symptoms, signs found in clinical examination, and clinical investigations of increasing invasiveness ending in neuropathology. The addition of each successive class of information increases the likelihood that the correct diagnosis is being made, as seen in the revised case definition.

In order to help countries with limited resources, the revised case definition provides specific information to allow for the classification of suspected cases as *Possible vCJD*. To achieve this aim, clinical characteristics that are described in the document should be considered.

Annexes to the document include the case definition, location of reference centres to assist in the diagnosis of CJD, a bibliography and technical information regarding specific diagnostic procedures such as CSF testing, MRI, tonsil biopsy, EEG and pathology.